

Figures:

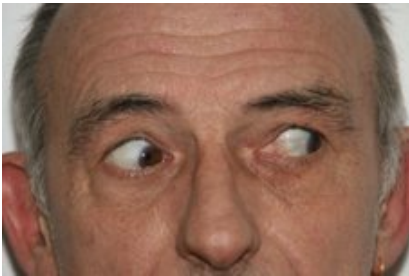
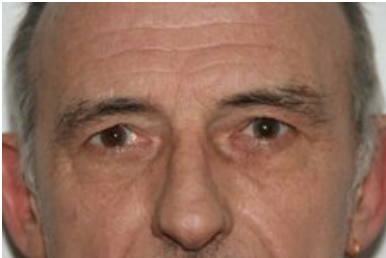
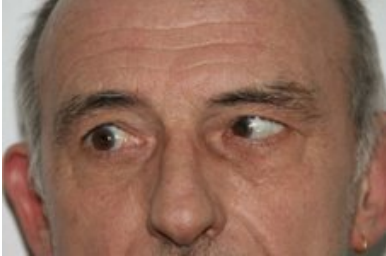Figure 1: patient #1 following lengthening of posterior segment of the LR in his right eye, with a temporal fascia spacer, through a lateral orbitotomy.

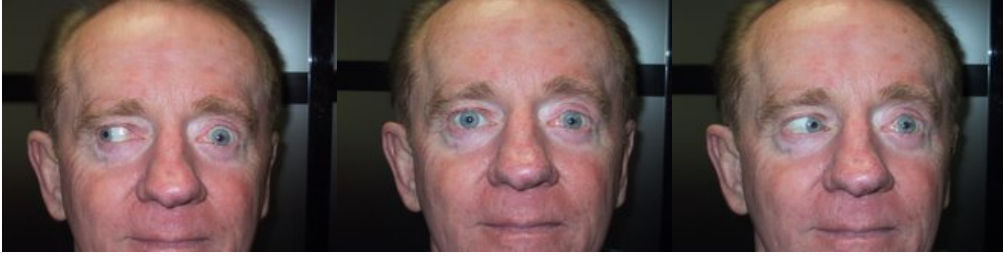

Figure 2 : patient # 2 following excision of left posterior LR remnants through a lateral orbitotomy.

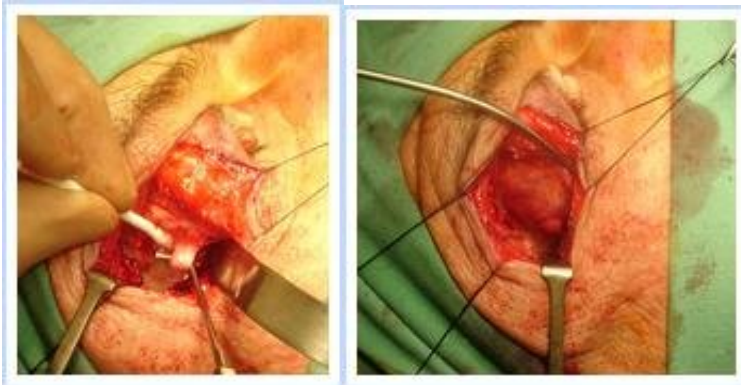


Figure 3: Lateral Orbitotomy view on right side. Left side shows LR muscle lifted by a squint hook after periorbital incision.