

# Lateral Orbitotomy in the Management of Challenging Exotropia

Claudia Yahalom, MD; Alan McNab, MD; Guy Ben Simon, MD; Lionel Kowal, MD

## ABSTRACT

The authors present an unorthodox surgical approach to reach the posterior segment of the lateral rectus muscle through a lateral orbitotomy and to manage difficult cases of recurrent exotropia. A review of the records of two patients with recurrent exotropia was done. After an anterior approach had been demonstrated to be inadequate due to shortening or fibrosis of the anterior part of this muscle following repeated surgeries, both patients underwent a lateral orbitotomy to reach the posterior segment of the lateral rectus muscle. Both patients achieved satisfactory ocular alignment following surgery with stable results, showing that this approach is a safe and effective surgical procedure. [J Pediatr Ophthalmol Strabismus 2009;46:000-000.]

## INTRODUCTION

Surgical treatment of large-angle exotropia frequently requires large lateral rectus muscle recessions as part of the surgical plan to regain good ocular alignment. In some challenging cases of exotropia, such as third nerve palsy, sensory exotropia, and Duane syndrome, new alternative surgical techniques to obtain and maintain alignment of the eye have been described.<sup>1-6</sup> There are still cases where the unopposed lateral rectus muscle keeps pulling the eye back to exotropia, even though all available techniques have been tried or are not feasible anymore due to shortening or scarring of the lateral rectus muscle. The aim of this study was to describe and evaluate the results of a new surgical approach for inactivation of the lateral

rectus muscle (after being unsuccessfully operated on several times) by its posterior disinsertion or extension through a lateral orbitotomy.

## METHODS

The records of two patients with recurrent large-angle exotropia were reviewed. Both patients underwent a lateral orbitotomy<sup>7</sup> to reach the posterior segment of the lateral rectus muscle. The lateral rectus muscle function was modified by either a posterior lengthening or extirpation of the muscle.

During the lateral orbitotomy technique<sup>8</sup> (Fig. 1), a skin incision is made in the lateral portion of the upper eyelid crease and extended inferolaterally in a skin fold toward the zygomatic arch. The lateral orbital rim is exposed by raising skin and muscle flaps, and the periosteum over the rim is incised and elevated, exposing the entire lateral rim and the inner aspect of the lateral orbital wall. Bone cuts are made using a saw just superior to the level of the zygomatic arch and at approximately the level of the zygomaticofrontal suture. The lateral wall is outfractured, removed, and kept in moist gauze. The periorbita is incised at the level of the lateral rectus muscle and then the lateral rectus muscle is identified and elevated on a squint hook. It may be divided and a spacer added or a segment may be excised.

To harvest the temporal fascia, the skin and muscle flap of the incision is dissected posteriorly beyond the lateral orbital rim to expose the anterior portion of the temporal fascia. A strip approximately 8 to 10 mm wide and approximately 15 mm long

---

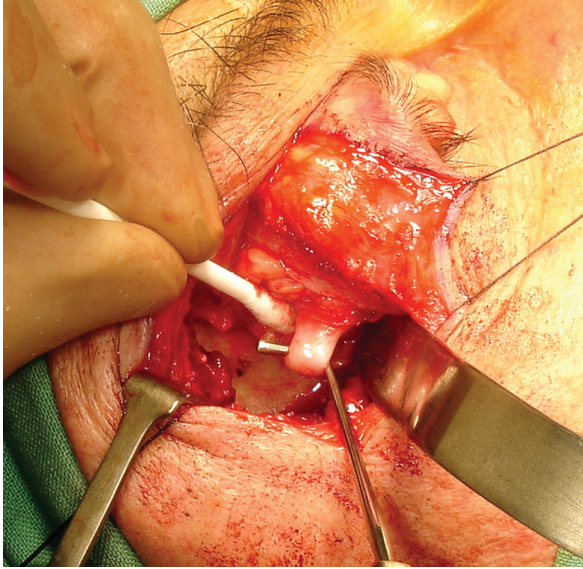
*From the Centre for Eye Research Australia and Ocular Motility Clinic (CY, LK), and the Orbital Plastic and Lacrimal Clinic (AM, GB), Royal Victorian Eye and Ear Infirmary, Melbourne, Australia; and the Hadassah Medical Center (CY), Jerusalem, Israel.*

*Originally submitted March 5, 2007. Accepted for publication October 4, 2007.*

*The authors have no financial or proprietary interest in the materials presented herein.*

*The authors thank the patient who suggested the basic plan for the operation.*

*Address correspondence to Lionel Kowal, MD, Eye and Ear Hospital, Gisborne 32, Melbourne, Victoria, Australia.*



**Figure 1.** Photograph showing the lateral rectus muscle lifted.

is harvested by sharp dissection. The lateral rectus muscle is exposed in the standard fashion used in a lateral orbitotomy, with a squint hook passed under its belly at approximately the junction of its middle and anterior third. Two 5-0 polyester sutures are placed in its superior and inferior border behind the squint hook before dividing the belly; these sutures are then used to attach the fascial graft to the posterior stump of muscle and the anterior end of the graft sutures to the anterior stump of muscle in the same manner. At the end of surgery, the periorbita is sutured and the bone is positioned back in place and sutured with heavy nylon through small burr holes. The periosteal lining is resutured and the skin is sutured in layers.

## CASE REPORTS

### Case 1

A 59-year-old man had an ocular history of right eye trauma with retinal detachment repair (silicone band and explant) at age 9 years. At 21 years, he underwent his first exotropia surgery. At 41 years, a recurrent retinal detachment occurred with further retinal surgery. His visual acuity was 6/12 in his right eye (with a +9.00 diopter [D] contact lens) and 6/6 in his left eye. He had a 50 prism diopters (PD) exotropia in his right eye and complained of diplopia when wearing the contact lens.

In 1997, the patient underwent a right eye lateral rectus exploration during which the muscle was found “superglued” to the sclera and dissection was

not feasible due to scarring. Several options were offered to the patient to improve the right eye alignment, including botulinum toxin injection to the lateral rectus muscle and fascia lata to tether the eye<sup>3</sup> (both procedures in the right eye) and surgery for exotropia in his left eye. The patient declined surgery to his left eye and did not want the right eye motility to be affected by the fascia lata procedure.

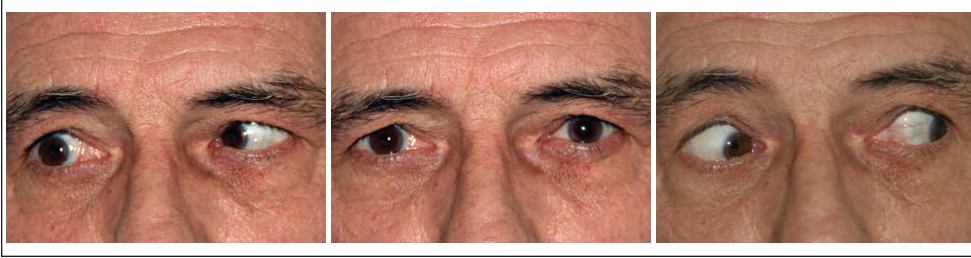
A possibility of lengthening the right lateral rectus muscle farther back in the orbit using a spacer was raised. A lateral orbitotomy was performed with lengthening of the posterior segment of the lateral rectus muscle with a temporal fascia spacer. Eighteen months after surgery, a small, stable angle of residual exotropia was found (20 PD exotropia), with improved cosmetics and near normal versions (Fig. 2).

### Case 2

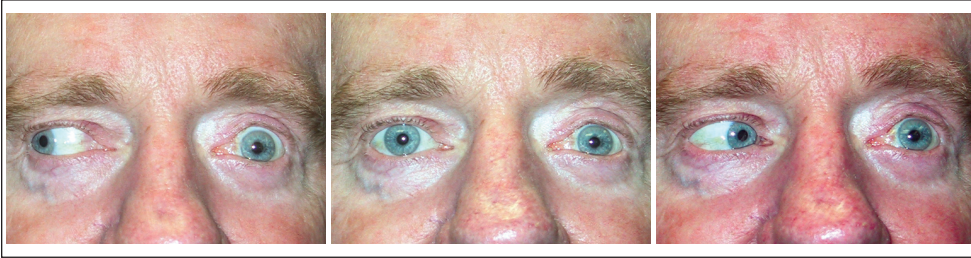A 55-year-old man had an ocular history of left eye blindness due to traumatic optic neuropathy and left third nerve palsy following an accident at 18 years of age. He had undergone strabismus surgery four times since he was 20 years old with recurrent left eye exotropia. On presentation at 50 years of age, his visual acuity was 6/5 in the right eye and no light perception in the left eye. Ocular movements showed underaction of the superior, medial, and inferior rectus muscles, which is consistent with third nerve palsy. Force generation test showed no medial rectus force generation and forced duction test revealed no restrictions in left eye movements. The Krimsky test exhibited left eye exotropia of 70 PD.

A left lateral rectus muscle disinsertion and suturing to the periosteum was planned.<sup>1,2</sup> At surgery, the muscle was found 10 mm behind the original insertion and it was not possible to suture it to the periosteum because it had been shortened. The anterior 10 mm of the lateral rectus muscle was excised and residual lateral rectus muscle was injected with acetylcholine chloride. A left medial rectus resection of 6 mm was performed.

Although the result was excellent 1 week after surgery, there was a quick recurrence of his exotropia. Ten weeks after surgery, there was a left exotropia of 50 PD. Magnetic resonance imaging of the orbits showed reattachment of lateral rectus muscle stump to the sclera near the level of the equator. The patient requested further surgery to reach cosmetic alignment.



**Figure 2.** Case 1 following lengthening of the posterior segment of the lateral rectus muscle in the right eye with a temporal fascia spacer through a lateral orbitotomy.



**Figure 3.** Case 2 following excision of the left posterior lateral rectus muscle through a lateral orbitotomy.

Lateral orbitotomy was performed, with excision of left posterior lateral rectus muscle remnants 15 to 20 mm. On subsequent follow-ups, the patient had a left exodeviation of 18 PD and remained stable for 5 years (Fig. 3). The patient was pleased with the improved appearance.

### DISCUSSION

The surgical management of recurrent exotropia is one of the most difficult problems facing the strabismus surgeon because any additional surgical procedures on the lateral rectus muscle become difficult due to scarring and shortening of the muscle. Lateral orbitotomy is a difficult procedure that should only be performed by a trained oculoplastic surgeon. Lateral orbitotomy for posterior lengthening or extirpation of the lateral rectus muscle in resistant exotropia is a novel, safe, and effective surgical procedure for restoring ocular alignment in persistent exodeviation and may be a useful addition to the current surgical techniques for the manage-

ment of strabismus secondary to third nerve palsy and other conditions resulting in resistant and recurrent exotropia.

### REFERENCES

1. Velez F, Thacker N, Britt M, Alcorn D, Foster R, Rosenbaum A. Rectus muscle orbital wall fixation: a reversible profound weakening procedure. *J AAPOS*. 2004;8:473-480.
2. Morad Y, Kowal L, Scott A. Lateral rectus muscle disinsertion and reattachment to the lateral orbital wall. *Br J Ophthalmol*. 2005;89:983-985.
3. Salazar-Leon JA, Ramirez-Ortiz MA, Salas-Vargas M. The surgical correction of paralytic strabismus using fascia lata. *J Pediatr Ophthalmol Strabismus*. 1998;35:27-32.
4. Sato M, Maeda M, Ohmura T, et al. Myectomy of lateral rectus muscle for third nerve palsy. *Jpn J Ophthalmol*. 2000;44:555-558.
5. Srivastava KK, Sundaresh K, Vijayalakshmi P. A new surgical technique for ocular fixation in congenital third nerve palsy. *J AAPOS*. 2004;8:371-377.
6. Morad Y, Nemet P. Medial transposition of the lateral rectus muscle in combined third and fourth nerve palsy. *J AAPOS*. 2000;4:246-247.
7. Arai H, Sato K, Katsuta T, Rhoton AL Jr. Lateral approach to intraorbital lesions: anatomic and surgical considerations. *Neurosurgery*. 1996;39:1157-1163.
8. McNab AA. Lateral orbitotomy. In: AUTHOR NAME, *Manual of Ocular and Lacrimal Surgery*, 2nd ed. Oxford: Butterworth Heinemann; 1998:41-48.