

Case :FF

82 y o

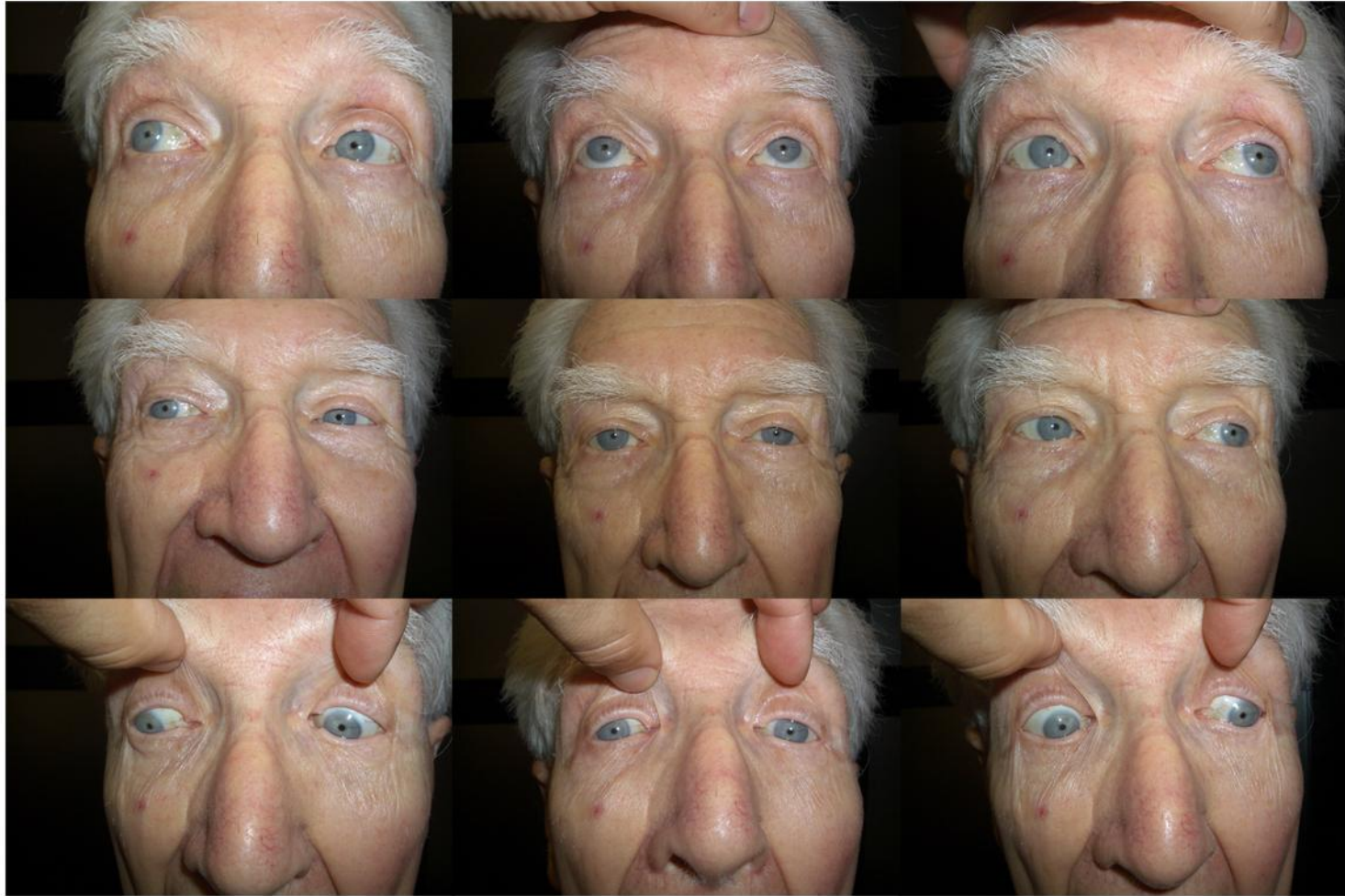8 y history of intermittent horizontal
diplopia

- 82 y o
- c/o: Intermittent Horizontal diplopia, mainly on left gaze, started 8 y ago
- POHx: BE cataract op (4 y ago)
- PHx: IHD
Hypercholesterolemia
AF
Pernicious anemia
Hip # op 9/2010

Examination

- VA cc RE 6/9 LE 6/6
- IOP: 17/18
- Slit Lamp - normal

BE elevate
incompletely.



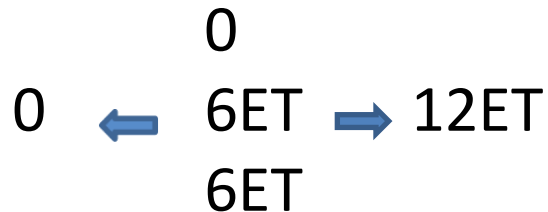
L gaze – L
depression
reduced.

R gaze – L
elevation
reduced

No obvious aBduction deficit
No LT gaze paresis

FF, 85yo

- Horizontal Deviation:



- Normal saccades [horizontal & oblique]
- Prescribed glasses:
 - 8pd BO, 2pd BU LE (single vision).

Sent for an MRI...

Image size: 512 x 512

S

072571 (84 y , 83 y)

View size: 635 x 635

Orbits - Exclude Patholo - Cor T1 (Thin)

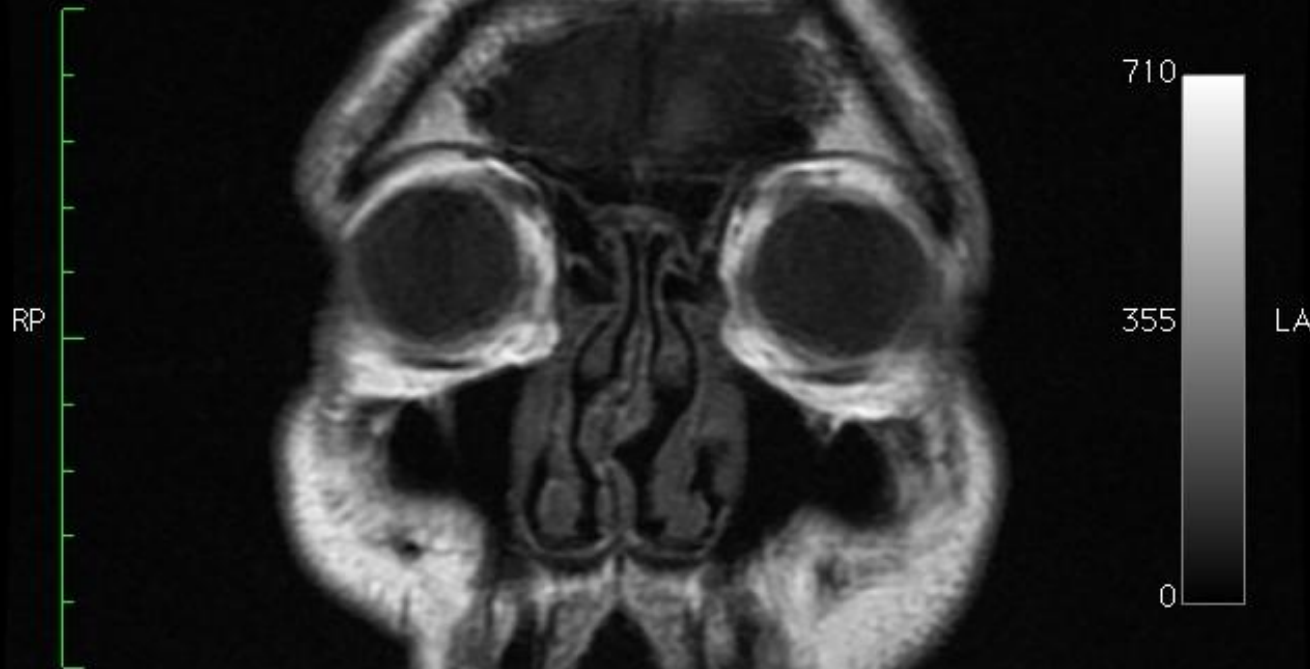
WL: 355 WW: 710

27408

X: 71 px Y: 506 px Value: 49.00

8

X: -79.68 mm Y: -74.43 mm Z: -121.17 mm



Zoom: 124% Angle: 0

TE: 14.512 TR: 440

Im: 1/24 A (A -> P)

FS: 1.5

Uncompressed

7/03/11 3:23:58 PM

Thickness: 3.00 mm Location: -70.74 mm

Made In OsiriX

Image size: 512 x 512

S

072571 (84 y , 83 y)

View size: 635 x 634

Orbits - Exclude Patholo - Cor T1 (Thin)

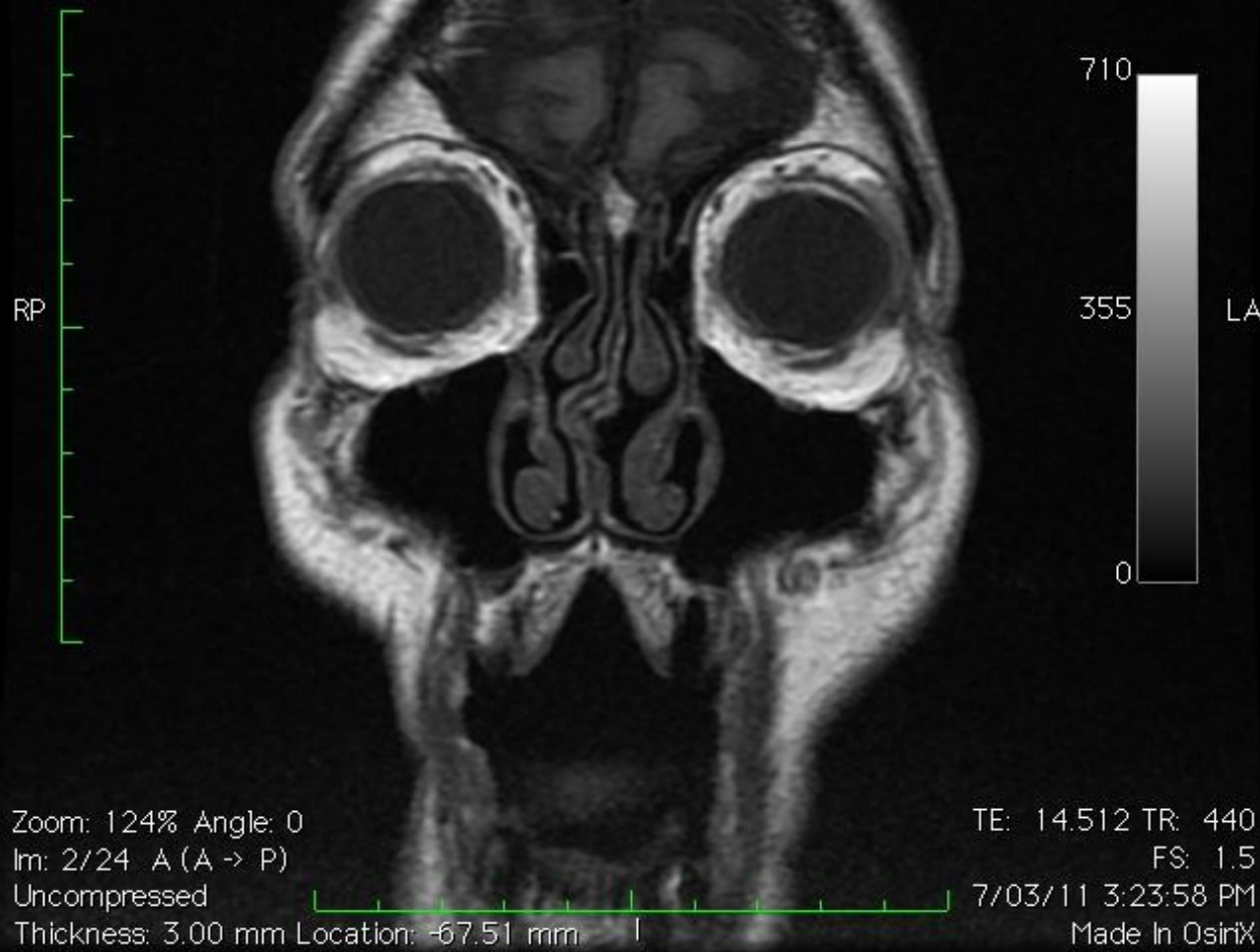
WL: 355 WW: 710

27408

X: 275 px Y: 506 px Value: 85.00

8

X: -1.16 mm Y: -87.88 mm Z: -117.26 mm



Zoom: 124% Angle: 0

TE: 14.512 TR: 440

Im: 2/24 A (A -> P)

FS: 1.5

Uncompressed

7/03/11 3:23:58 PM

Thickness: 3.00 mm Location: -67.51 mm I

Made In OsiriX

Image size: 512 x 512

S

072571 (84 y , 83 y)

View size: 635 x 635

Orbits - Exclude Patholo - Cor T1 (Thin)

WL: 355 WW: 710

27408

X: 275 px Y: 505 px Value: 108.00

8

X: -0.48 mm Y: -84.65 mm Z: -117.03 mm

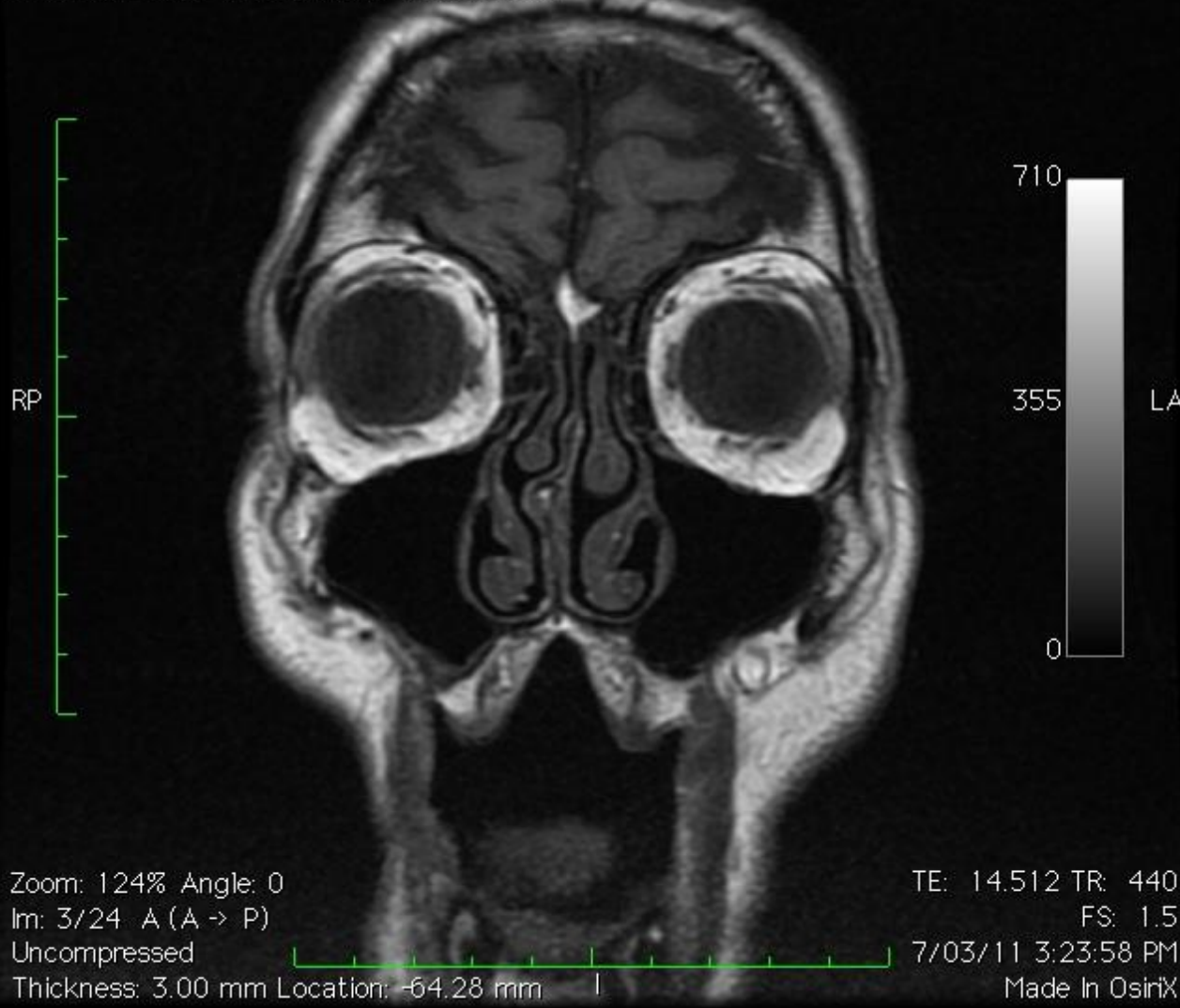


Image size: 512 x 512

S

072571 (84 y , 83 y)

View size: 635 x 635

Orbits - Exclude Patholo - Cor T1 (Thin)

WL: 355 WW: 710

27408

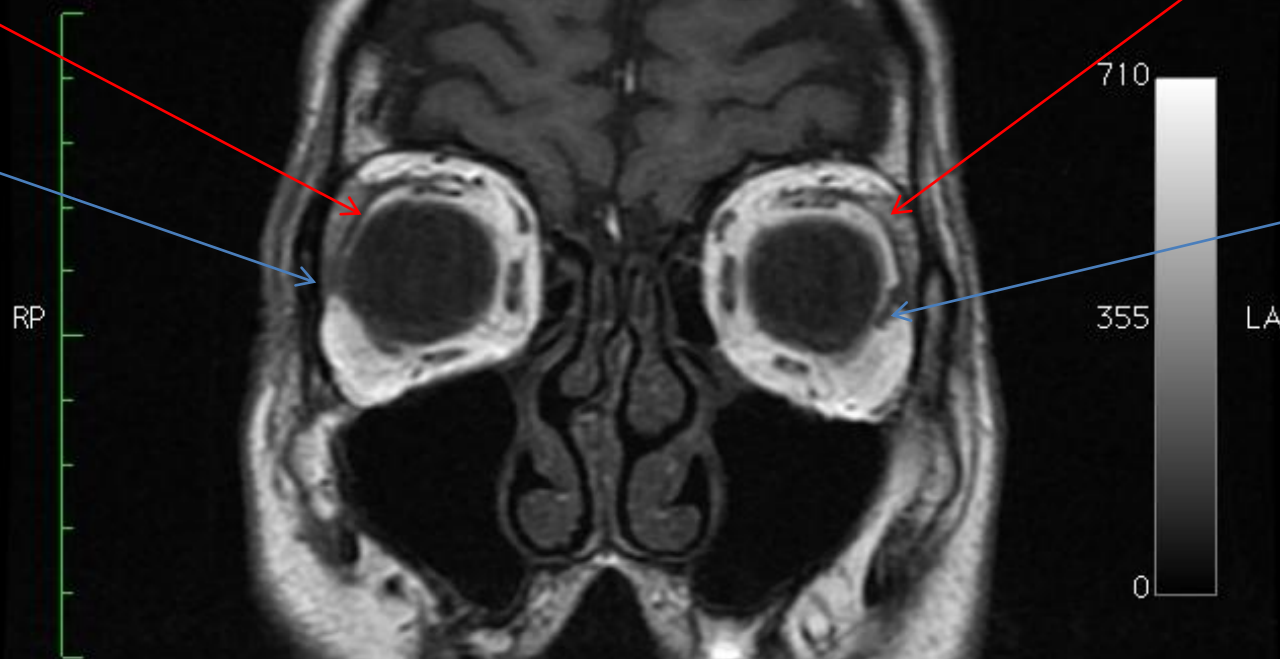
X: 275 px Y: 506 px Value: 95.00

8

X: 0.21 mm Y: -81.42 mm Z: -117.12 mm

Atrophy of Inter-muscular septum (LSR-LLR)

Lower & tilted position of LLR



Zoom: 124% Angle: 0

TE: 14.512 TR: 440

Im: 4/24 A (A -> P)

FS: 1.5

Uncompressed

7/03/11 3:23:58 PM

Thickness: 3.00 mm Location: -61.06 mm

Made In OsiriX

Image size: 512 x 512

S

072571 (84 y , 83 y)

View size: 635 x 635

Orbits - Exclude Patholo - Cor T1 (Thin)

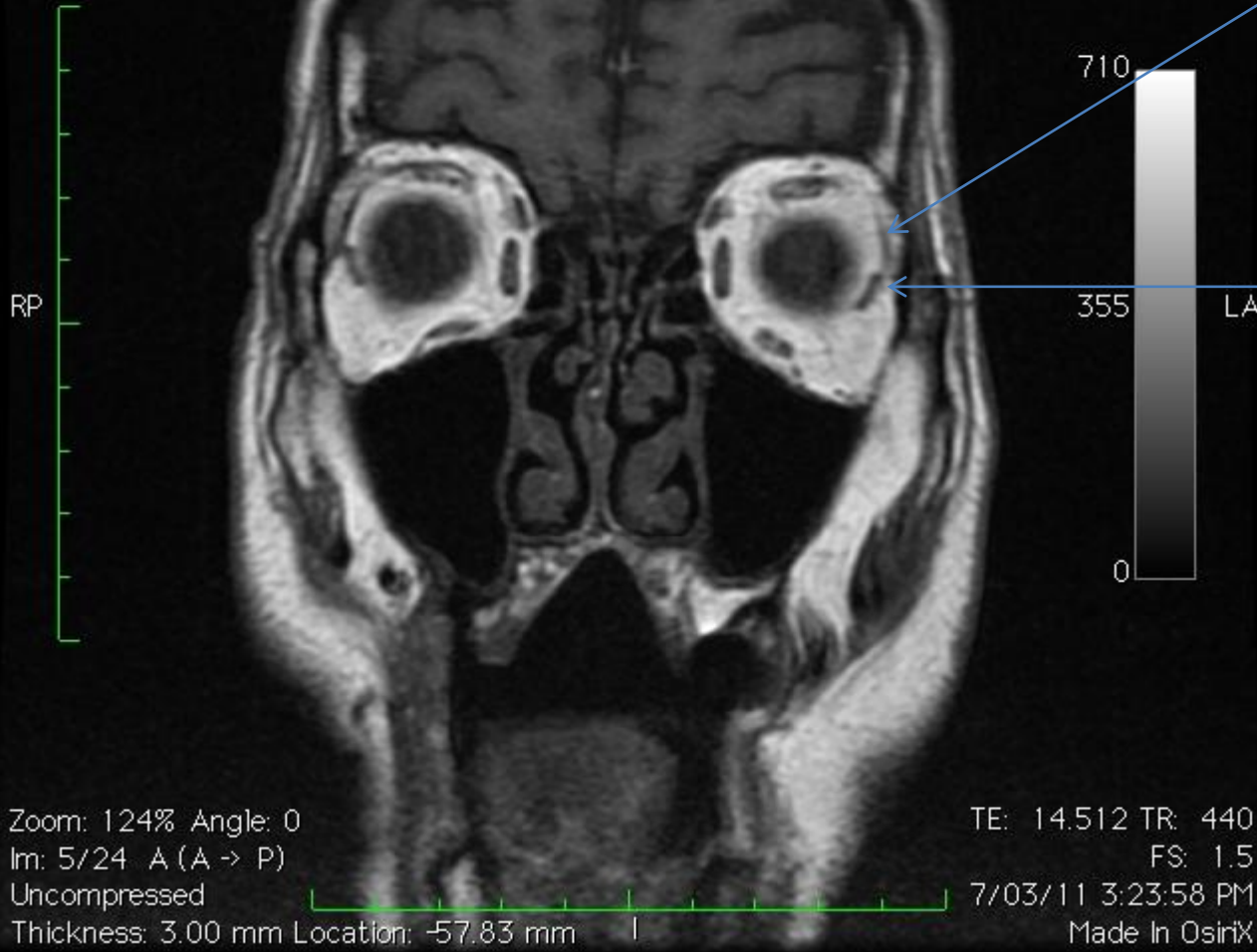WL: 355 WW: 710

27408

X: 275 px Y: 506 px Value: 65.00

8

X: 0.90 mm Y: -78.20 mm Z: -117.05 mm



Atrophy of Inter-muscular septum (LSR-LLR)

Lower & tilted position of LLR

Image size: 512 x 512

View size: 635 x 634

WL: 355 WW: 710

X: 275 px Y: 506 px Value: 125.00

X: 1.59 mm Y: -74.97 mm Z: -116.98 mm

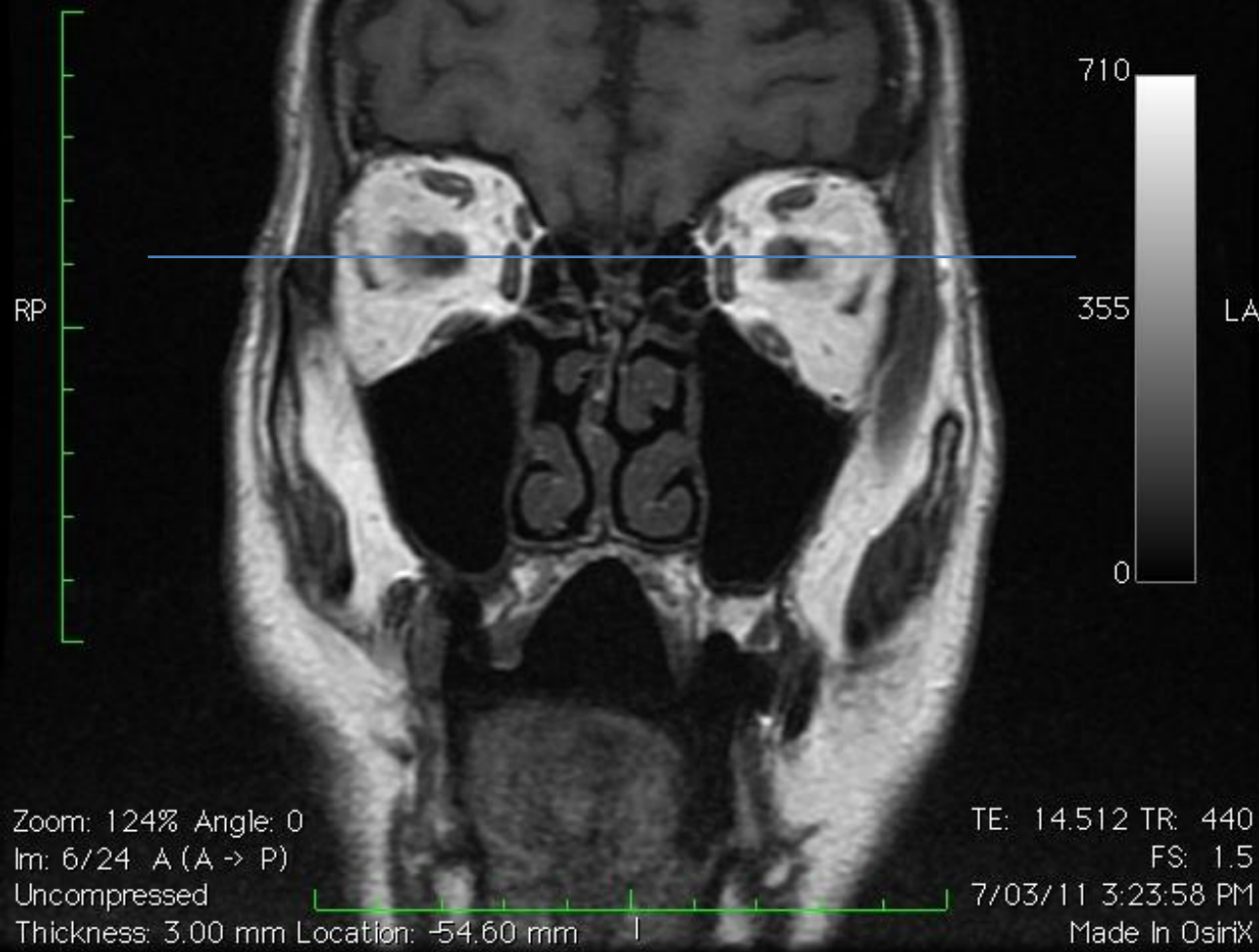
S

072571 (84 y , 83 y)

Orbits - Exclude Patholo - Cor T1 (Thin)

27408

8



RP

710

355

0

LA

Zoom: 124% Angle: 0

Im: 6/24 A (A -> P)

Uncompressed

Thickness: 3.00 mm Location: -54.60 mm

TE: 14.512 TR: 440

FS: 1.5

7/03/11 3:23:58 PM

Made In OsiriX

Lower & tilted position of LLR

Image size: 512 x 512

S

072571 (84 y , 83 y)

View size: 635 x 635

Orbits - Exclude Patholo - Cor T1 (Thin)

WL: 355 WW: 710

27408

X: 275 px Y: 505 px Value: 116.00

8

X: 2.27 mm Y: -71.75 mm Z: -116.75 mm

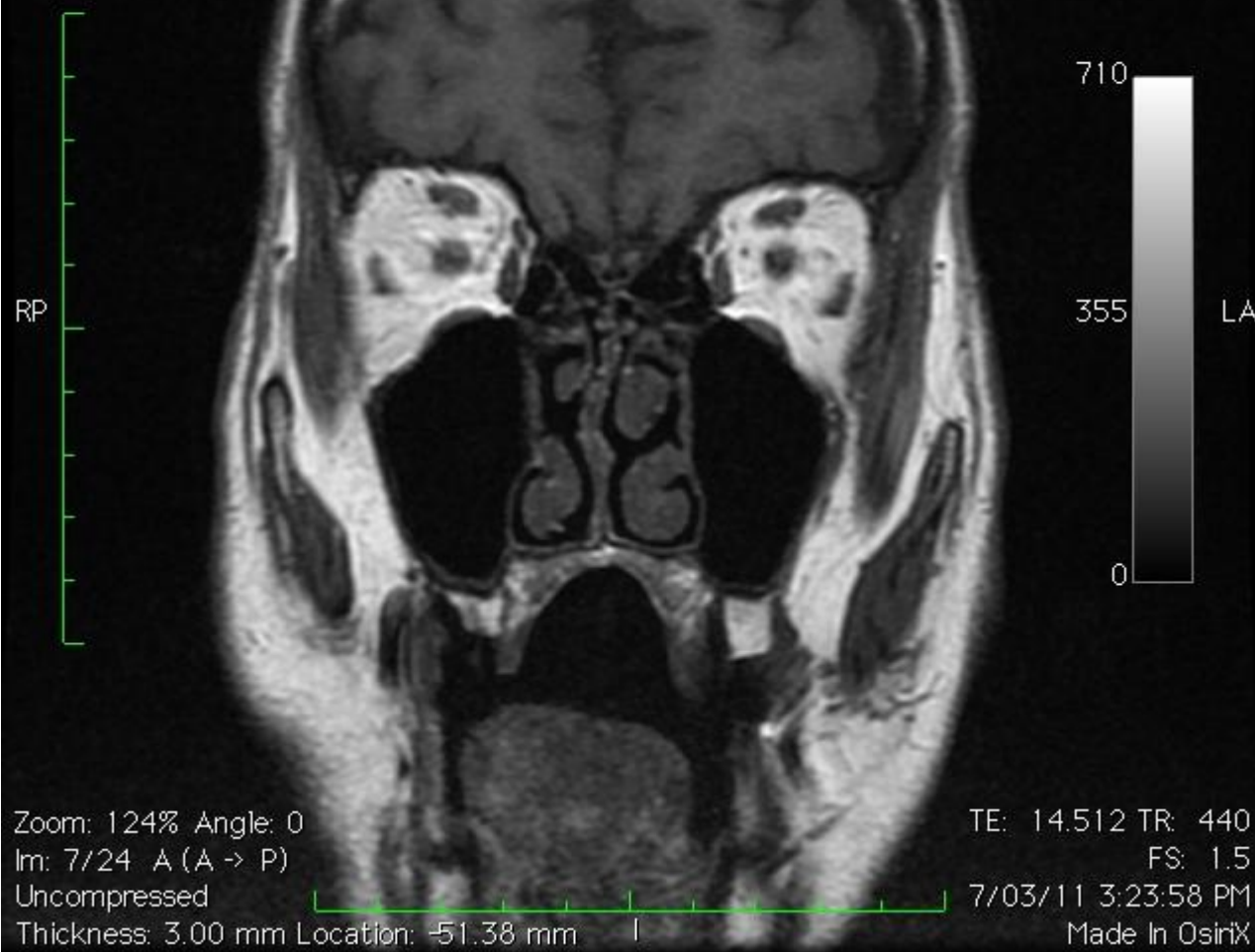


Image size: 512 x 512

S

072571 (84 y , 83 y)

View size: 635 x 635

Orbits - Exclude Patholo - Cor T1 (Thin)

WL: 355 WW: 710

27408

X: 275 px Y: 506 px Value: 96.00

8

X: 2.96 mm Y: -68.52 mm Z: -116.84 mm

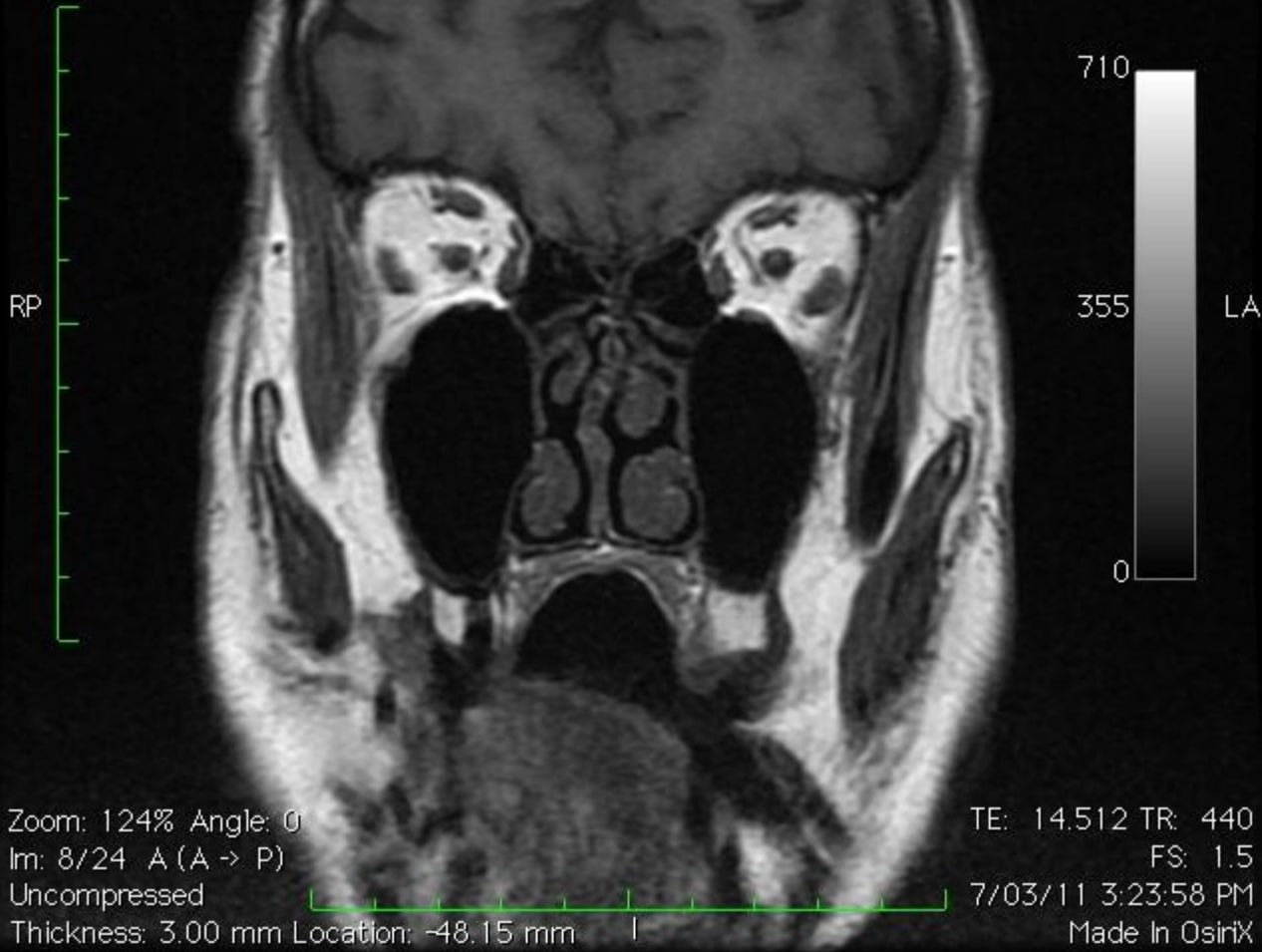


Image size: 512 x 512

S

072571 (84 y , 83 y)

View size: 635 x 635

Orbits - Exclude Patholo - Cor T1 (Thin)

WL: 355 WW: 710

27408

X: 275 px Y: 506 px Value: 112.00

8

X: 3.65 mm Y: -65.29 mm Z: -116.77 mm

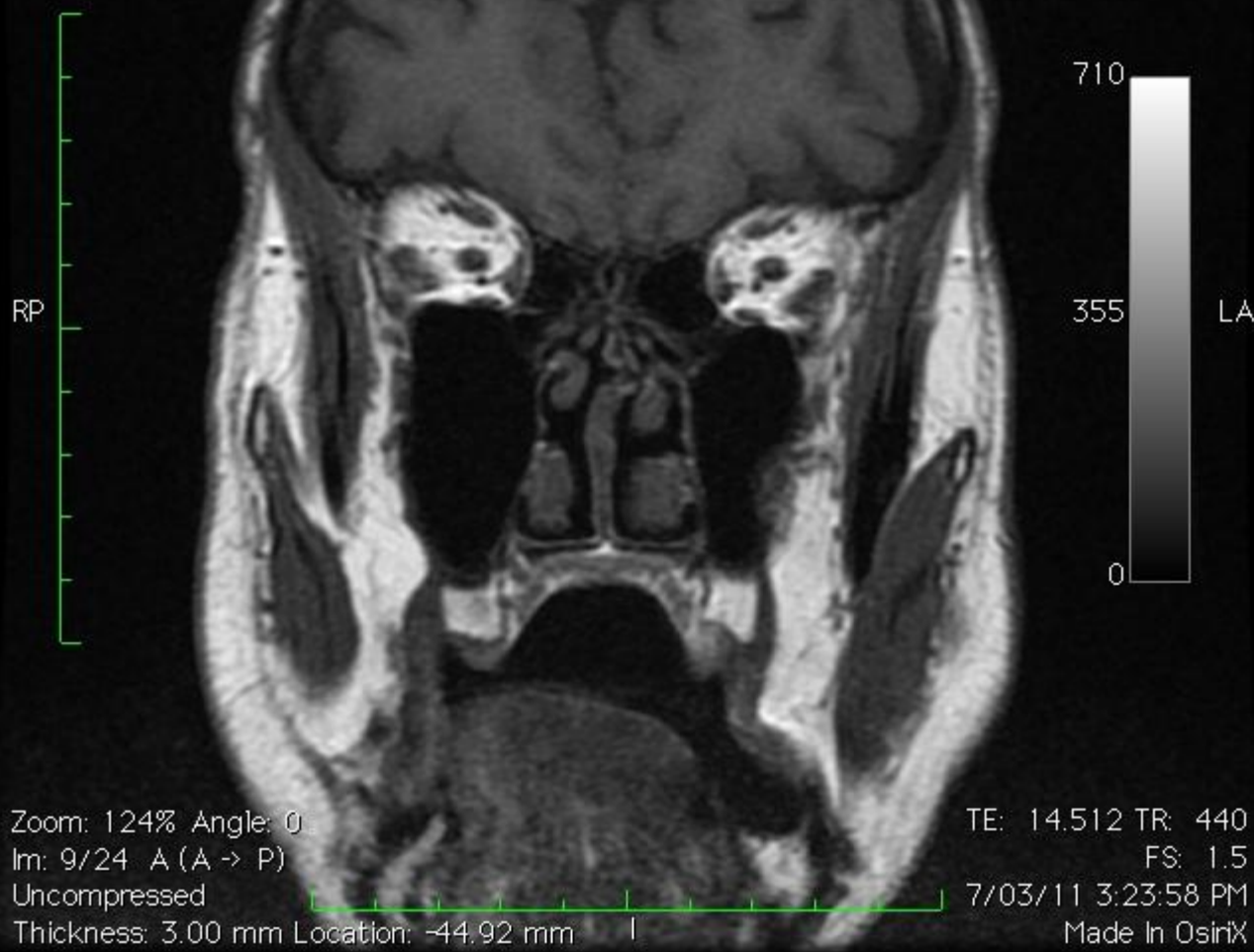


Image size: 512 x 512
View size: 635 x 635
WL: 355 WW: 710
X: 275 px Y: 506 px Value: 186.00
X: 4.34 mm Y: -62.06 mm Z: -116.70 mm

S

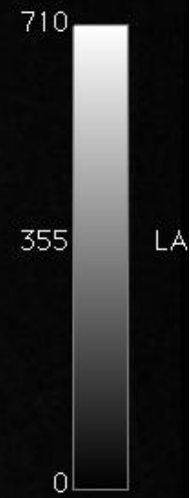072571 (84 y , 83 y)

Orbits -Exclude Patholo - Cor T1 (Thin)

27408

8

RP



Zoom: 124% Angle: 0
Im: 10/24 A (A -> P)
Uncompressed
Thickness: 3.00 mm Location: -41.70 mm

TE: 14.512 TR: 440
FS: 1.5
7/03/11 3:23:58 PM
Made In OsiriX

Image size: 512 x 512

S

072571 (84 y , 83 y)

View size: 635 x 635

Orbits - Exclude Patholo - Cor T1 (Thin)

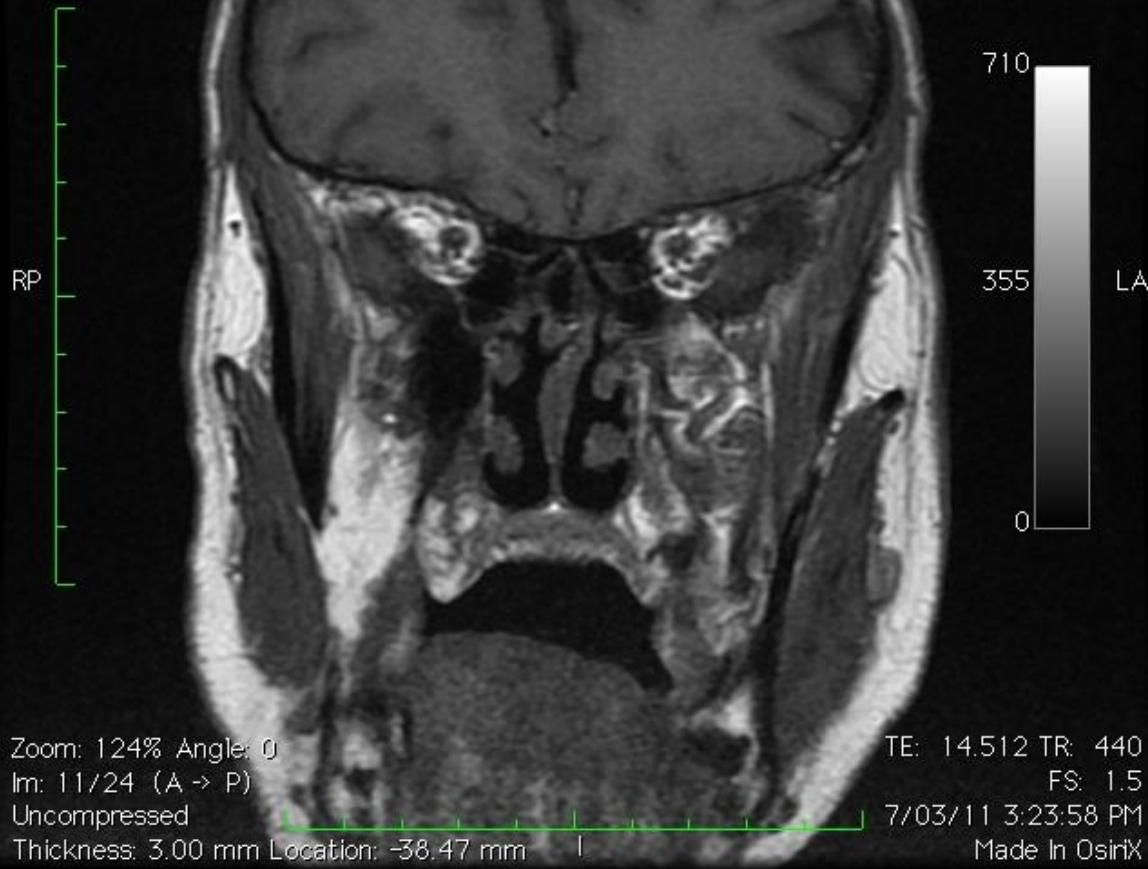WL: 355 WW: 710

27408

X: 275 px Y: 506 px Value: 152.00

8

X: 5.03 mm Y: -58.84 mm Z: -116.63 mm



Zoom: 124% Angle: 0

TE: 14.512 TR: 440

Im: 11/24 (A -> P)

FS: 1.5

Uncompressed

7/03/11 3:23:58 PM

Thickness: 3.00 mm Location: -38.47 mm

Made In OsiriX

Image size: 512 x 512

AR

072571 (84 y , 83 y)

View size: 634 x 635

Orbits - Exclude Patholo - AX T1 Thin

WL: 534 WW: 1069

27408

X: 272 px Y: 502 px Value: 418.00

10

X: 23.88 mm Y: 75.41 mm Z: 1.68 mm

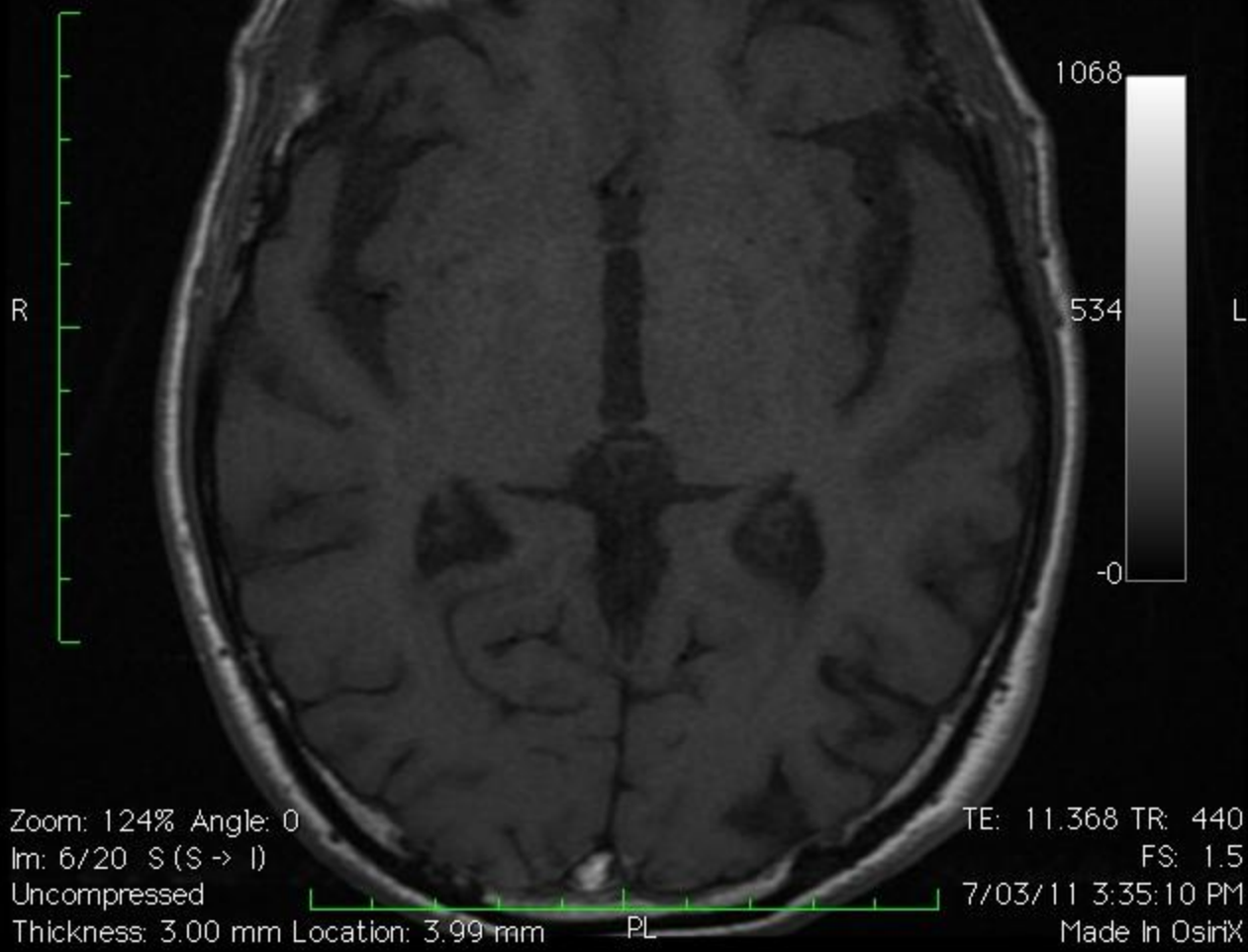


Image size: 512 x 512

AR

072571 (84 y , 83 y)

View size: 634 x 635

Orbits - Exclude Patholo - AX T1 Thin

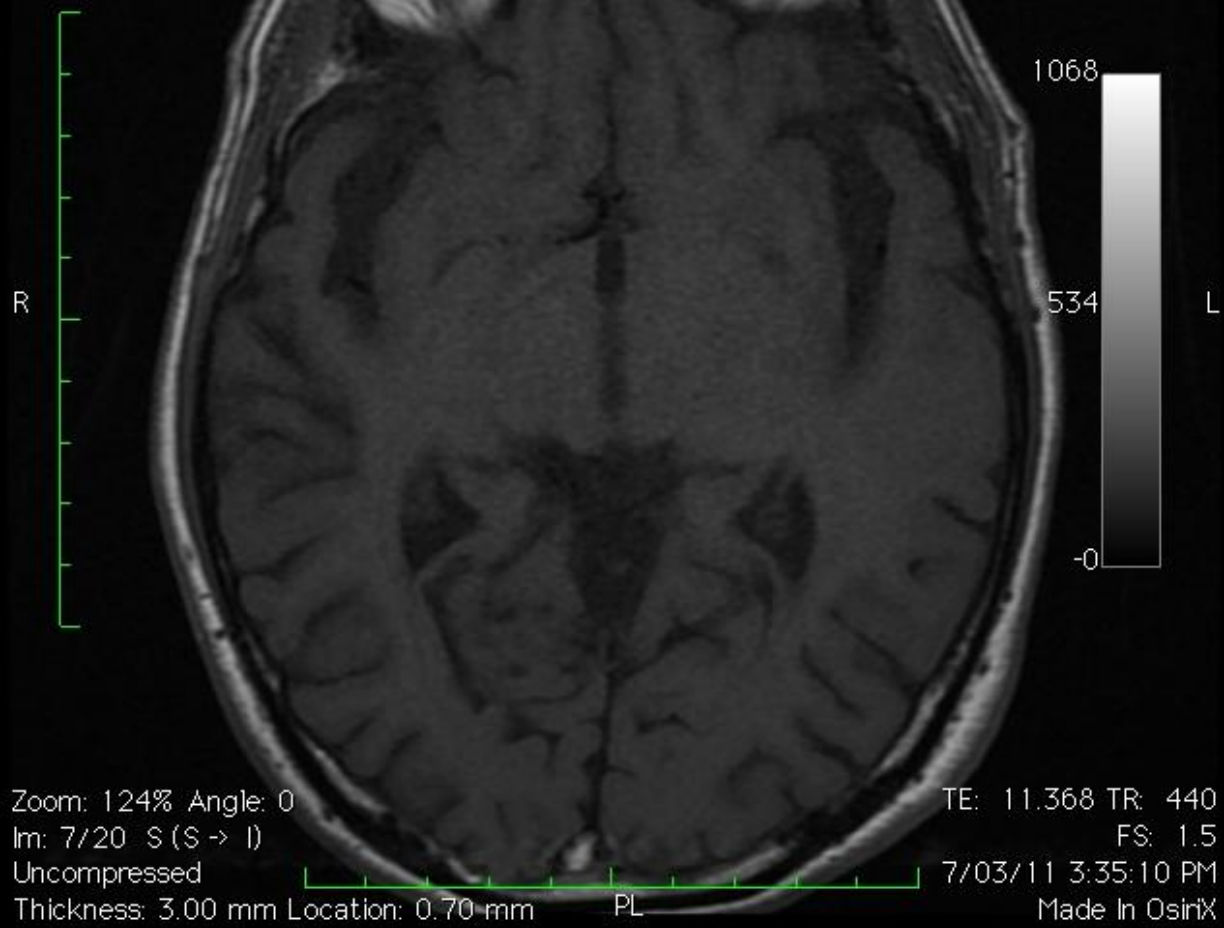
WL: 534 WW: 1069

27408

X: 272 px Y: 502 px Value: 155.00

10

X: 23.97 mm Y: 75.29 mm Z: -1.62 mm



Zoom: 124% Angle: 0

TE: 11.368 TR: 440

Im: 7/20 S (S -> I)

FS: 1.5

Uncompressed

7/03/11 3:35:10 PM

Thickness: 3.00 mm Location: 0.70 mm

PL

Made In OsiriX

Image size: 512 x 512

View size: 634 x 635

WL: 534 WW: 1069

X: 272 px Y: 502 px Value: 1.00

X: 24.07 mm Y: 75.16 mm Z: -4.91 mm

AR

072571 (84 y , 83 y)

Orbits -Exclude Patholo — AX T1 Thin

27408

10

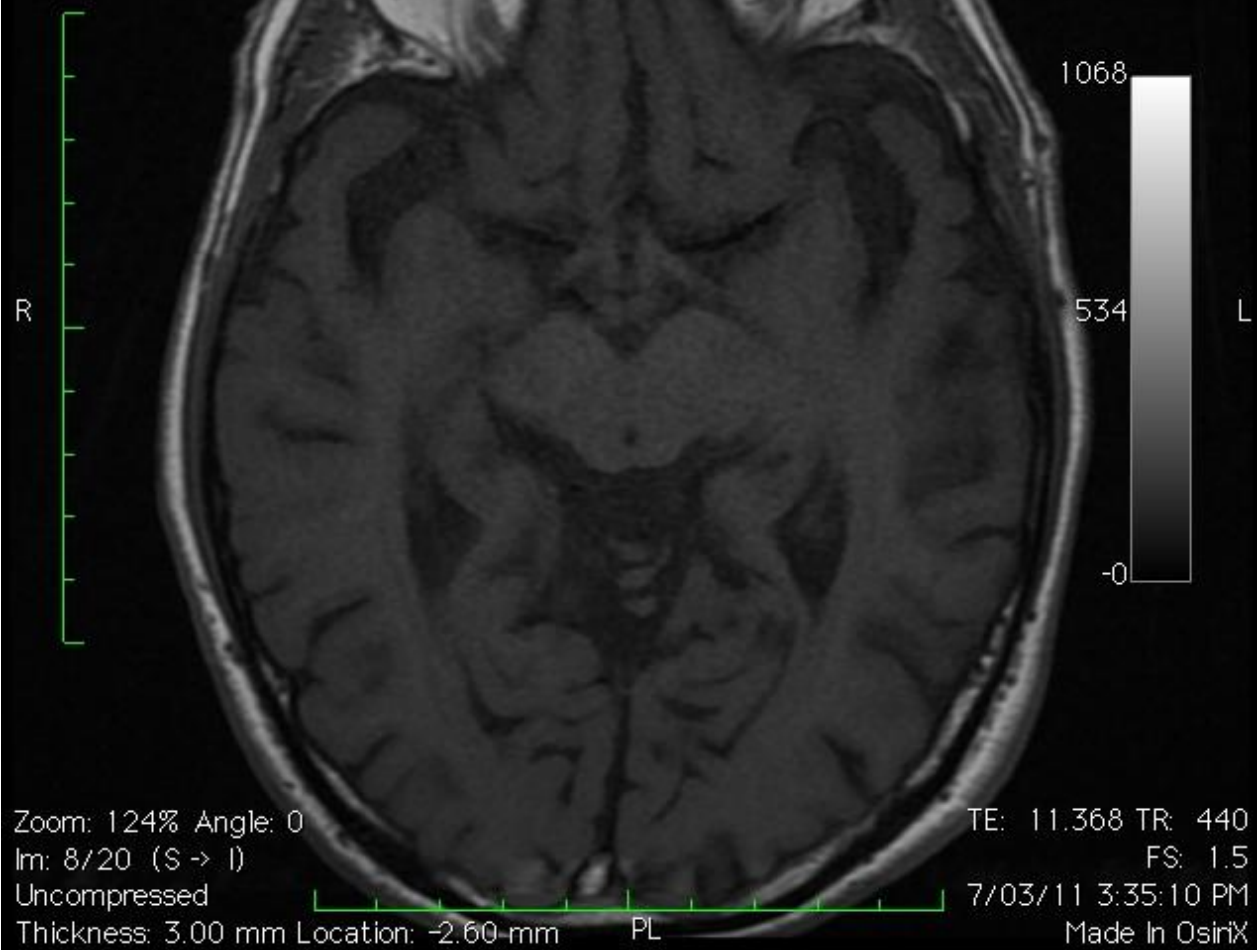


Image size: 512 x 512

AR

072571 (84 y , 83 y)

View size: 634 x 635

Orbits -Exclude Patholo - AX T1 Thin

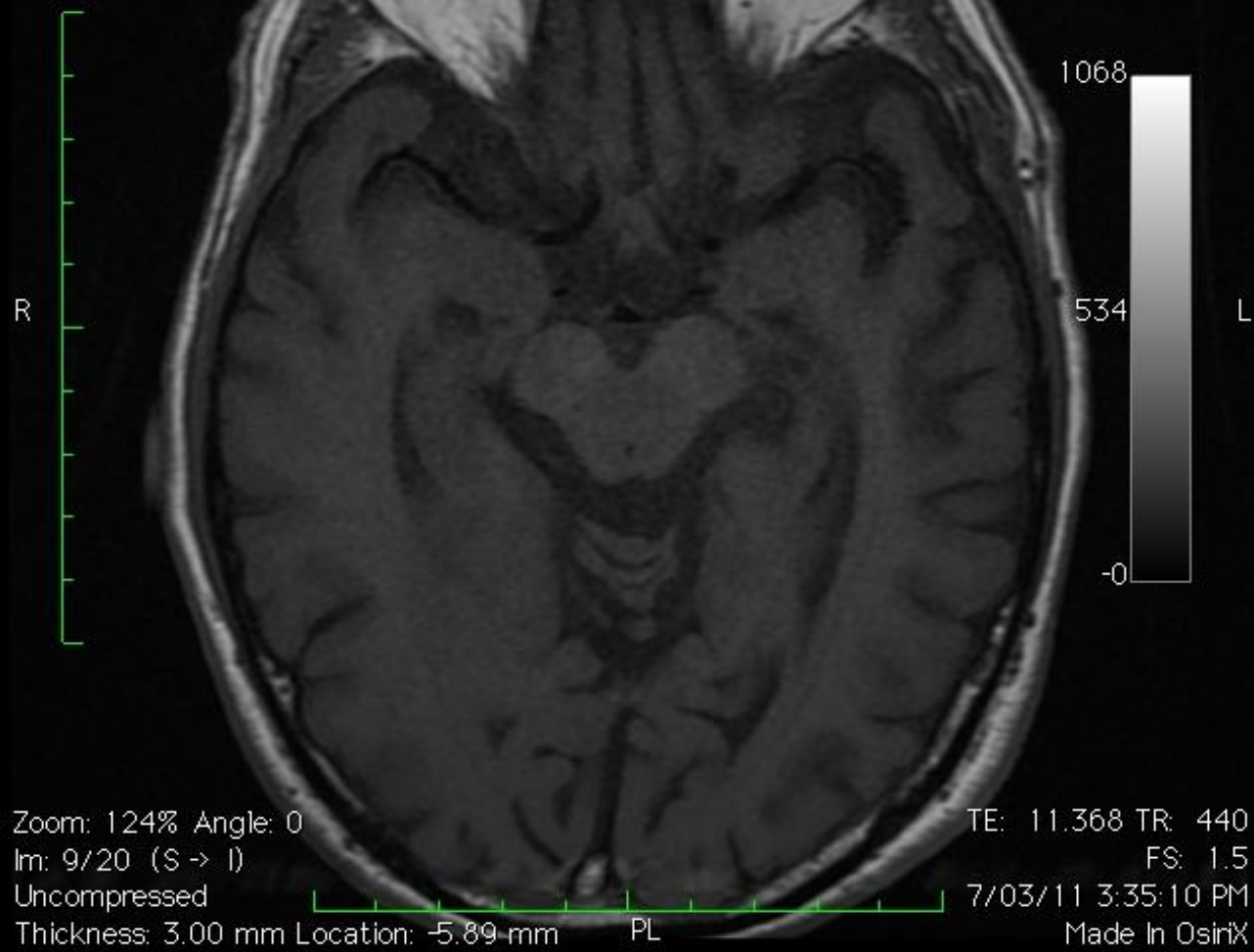
WL: 534 WW: 1069

27408

X: 272 px Y: 502 px Value: 20.00

10

X: 24.17 mm Y: 75.03 mm Z: -8.21 mm



R

L

Zoom: 124% Angle: 0

TE: 11.368 TR: 440

Im: 9/20 (S -> I)

FS: 1.5

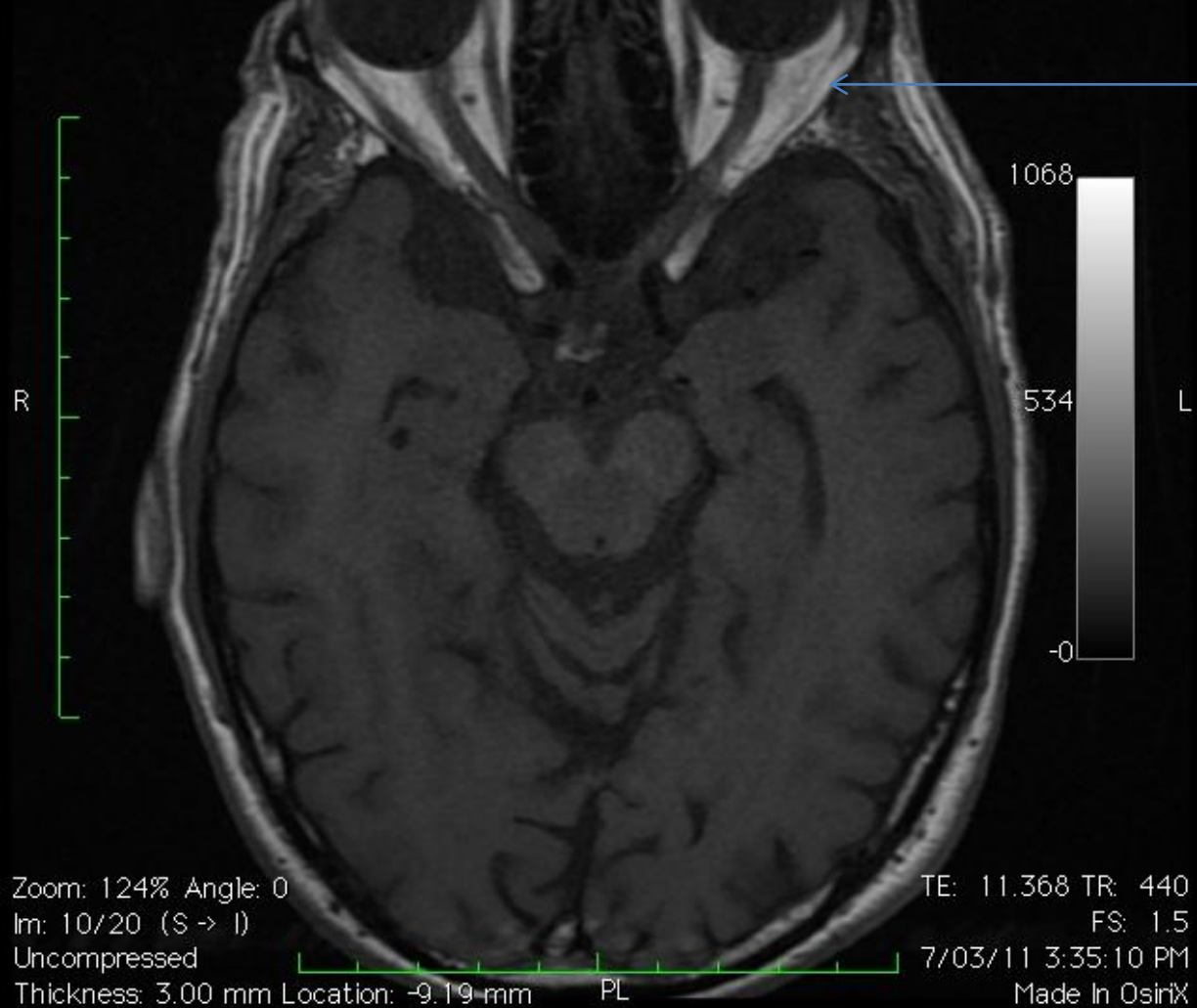
Uncompressed

7/03/11 3:35:10 PM

Thickness: 3.00 mm Location: -5.89 mm PL

Made In OsirX

Image size: 512 x 512 AR 072571 (84 y , 83 y)
View size: 634 x 635 Orbits - Exclude Patholo - AX T1 Thin
WL: 534 WW: 1069 27408
X: 272 px Y: 502 px Value: 12.00 10
X: 24.27 mm Y: 74.91 mm Z: -11.51 mm



LLR

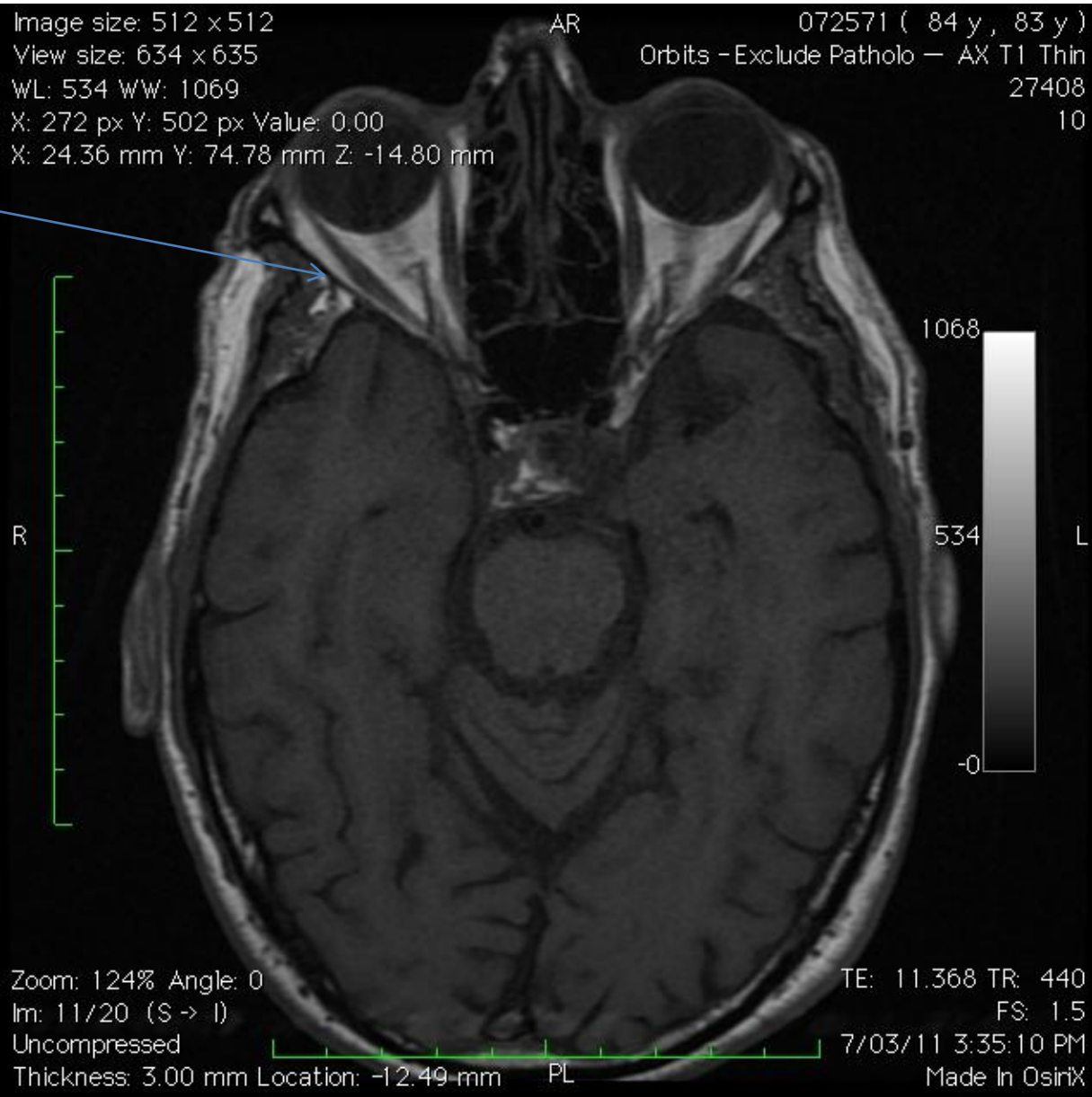


Image size: 512 x 512

AR

072571 (84 y , 83 y)

View size: 634 x 635

Orbits - Exclude Patholo - AX T1 Thin

WL: 534 WW: 1069

27408

X: 272 px Y: 502 px Value: 420.00

10

X: 24.56 mm Y: 74.53 mm Z: -21.40 mm

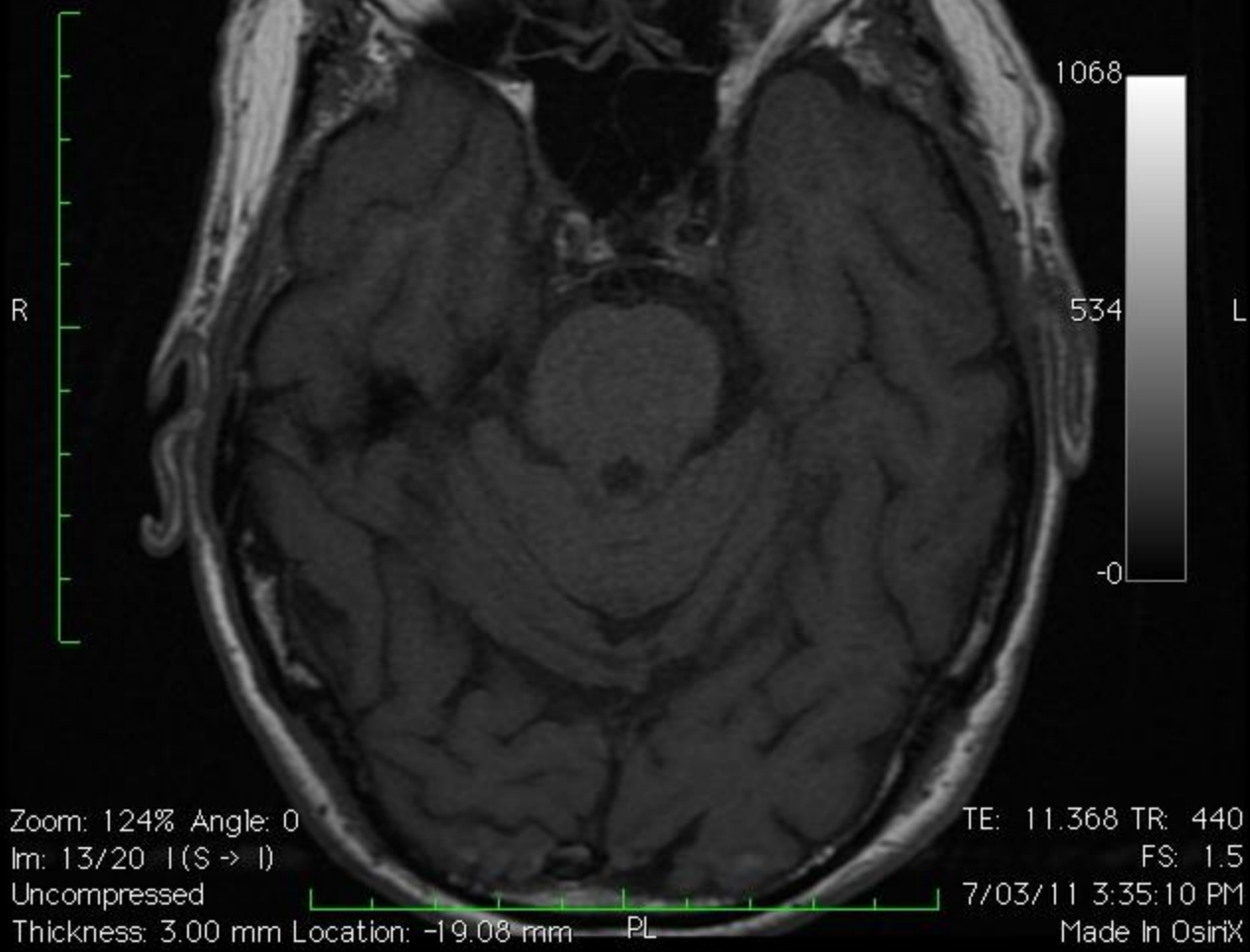


Image size: 512 x 512
View size: 634 x 635
WL: 534 WW: 1069
X: 272 px Y: 502 px Value: 374.00
X: 24.66 mm Y: 74.40 mm Z: -24.69 mm

AR

072571 (84 y , 83 y)
Orbits - Exclude Patholo - AX T1 Thin
27408
10

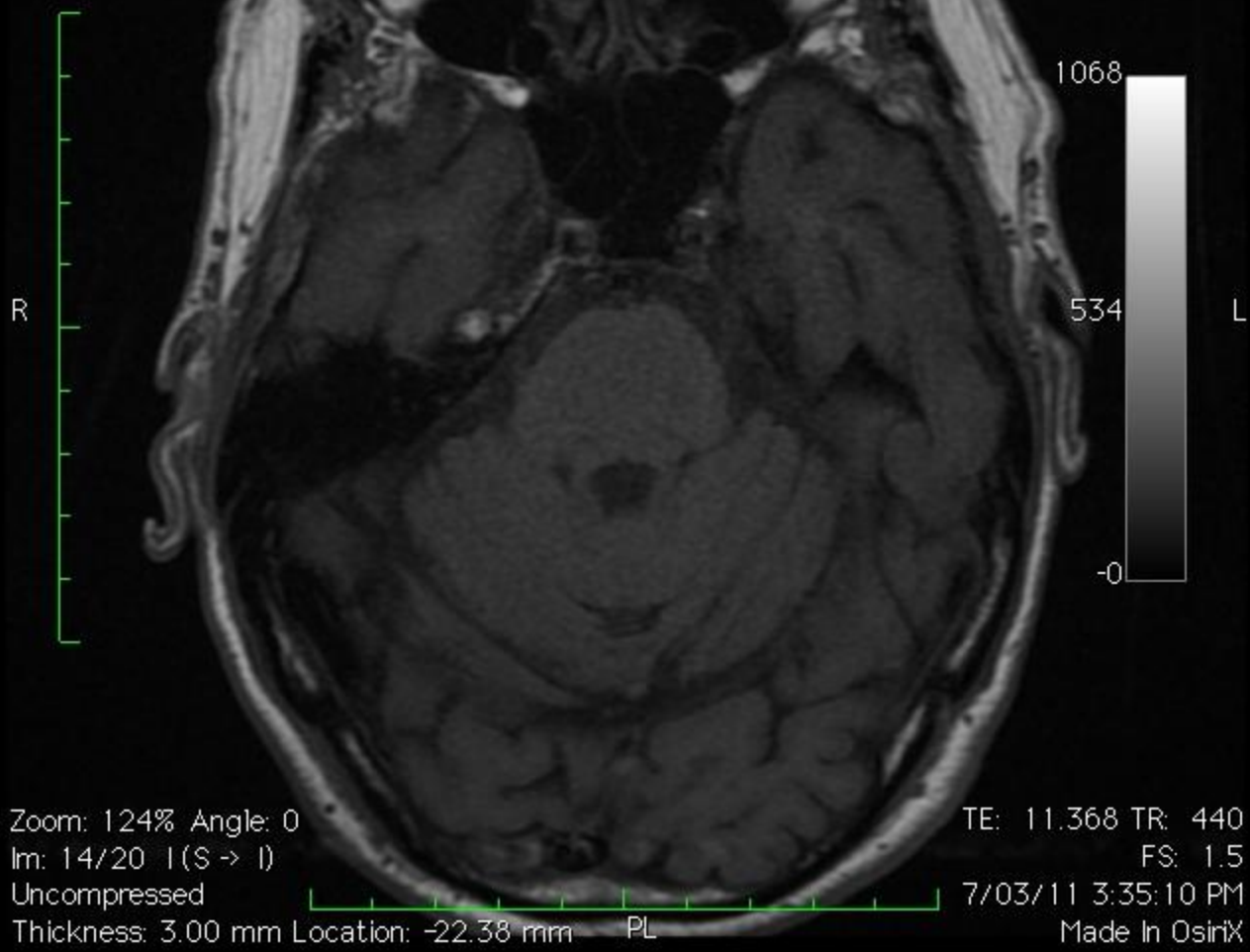


Image size: 512 x 512

View size: 634 x 635

WL: 534 WW: 1069

X: 272 px Y: 502 px Value: 278.00

X: 24.75 mm Y: 74.27 mm Z: -27.99 mm

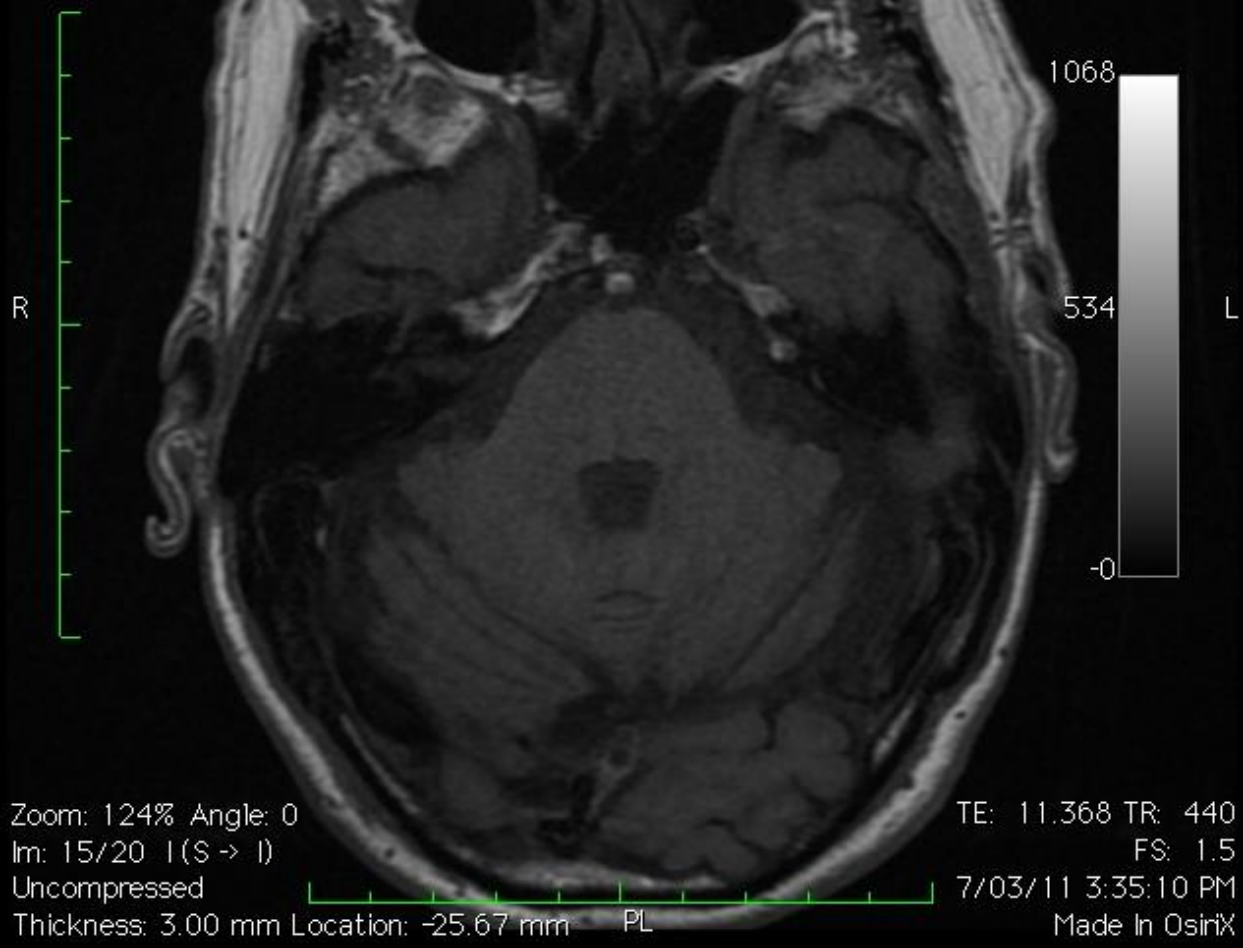
AR

072571 (84 y , 83 y)

Orbits - Exclude Patholo - AX T1 Thin

27408

10



Zoom: 124% Angle: 0

Im: 15/20 (S -> I)

Uncompressed

Thickness: 3.00 mm Location: -25.67 mm PL

TE: 11.368 TR: 440

FS: 1.5

7/03/11 3:35:10 PM

Made In Osirix

Discussion

'Saggy Eye' Syndrome

2 forms of presentation

1. Asymmetric and causes diplopia

“Heavy Eye” Syndrome in the Absence of High Myopia: A Connective Tissue Degeneration in Elderly Strabismic Patients.

Rutar T, Demer JL. [J AAPOS. 2009 February; 13\(1\): 36–44](#)

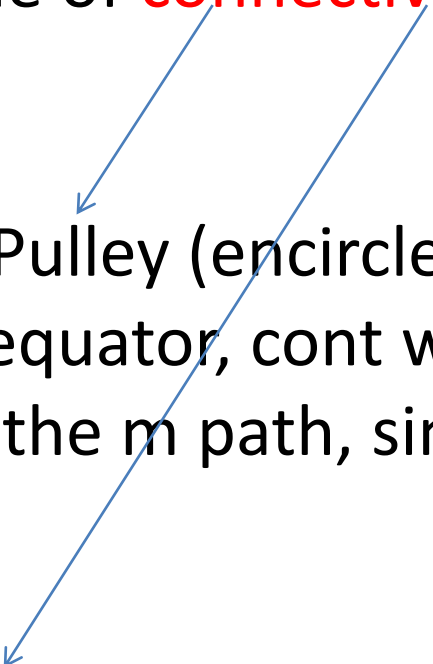
2. Impaired upgaze in elderly w/o diplopia

Effect of aging on human rectus extraocular muscle paths demonstrated by magnetic resonance imaging.

Clark RA, Demer JL. [Am J Ophthalmol. 2002 Dec;134\(6\):872-8.](#)

Background

The role of **connective tissues** on Ocular Motility



Pulley (encircles the rectus m, post to globe equator, cont with tenon's fascia and inflect the m path, similar to trochlea of SOM)

Intermuscular septa (couples the pulleys to one another)

LR-SR inter-muscular septa/ band

Degeneration of the LR-SR band may occur in elderly



Inf displacement of the LR & Pulley.



The new position of the LR changes its mechanical efficiency and induces a vertical effect as well.



ET& Hypotropia

*Similar to “heavy eye” synd in myopic strabismus fixus

METHODS

3 strabismic elderly pt's,
3 strabismic high myopes,
Compared to
12 orthotropic elderly.

Ophthalmic exam and orbital MRI
for the position of LR related to globe centroid &
LR-SR band.

“Heavy Eye” Syndrome in the Absence of High Myopia: A Connective Tissue Degeneration in Elderly Strabismic Patients. Rutar T, Demer JL.
[J AAPOS. 2009 February; 13\(1\): 36–44](#)

RESULTS- LRM position

2 strabismic pt's had Hypotropia,
1 had ET (AL = 24 mm, for myopes AL=31).

LR position of elderly strabismic pt's :4.6mm
inferior to globe centroid,
similar to that of high myopes (5.1 ± 3.2 mm).
For the orthotropic elderly subjects: only 2.1mm
($P=0.01$).

“Heavy Eye” Syndrome in the Absence of High Myopia: A Connective Tissue Degeneration in Elderly Strabismic Patients. [J AAPOS. 2009 February; 13\(1\): 36–44.](#)

LR-SR band

- By MRI, LR-SR band thinning, discontinuity, or displacement, was seen in:
 - 100% of strabismic elderly orbits,
 - 67% of strabismic myopic orbits,
 - and 12.5% of control (ortho) elderly.

“Heavy Eye” Syndrome in the Absence of High Myopia: A Connective Tissue Degeneration in Elderly Strabismic Patients. [J AAPOS. 2009 February; 13\(1\): 36–44.](#)

LR-SR band

- By MRI, LR-SR band thinning, discontinuity, or displacement, was seen in:
 - 100% of strabismic elderly orbits,
 - 67% of strabismic myopic orbits,
 - and 12.5% of control (ortho) elderly.

“Heavy Eye” Syndrome in the Absence of High Myopia: A Connective Tissue Degeneration in Elderly Strabismic Patients. [J AAPOS. 2009 February; 13\(1\): 36–44.](#)

- 12 elderly (65.2 y) compared with MRI images
12 younger subjects (28.5 y)
- **CONCLUSIONS**: The horizontal rectus EOM & pulley are displaced inf in the elderly ---> partially **converting horizontal rectus muscle force to depression.**

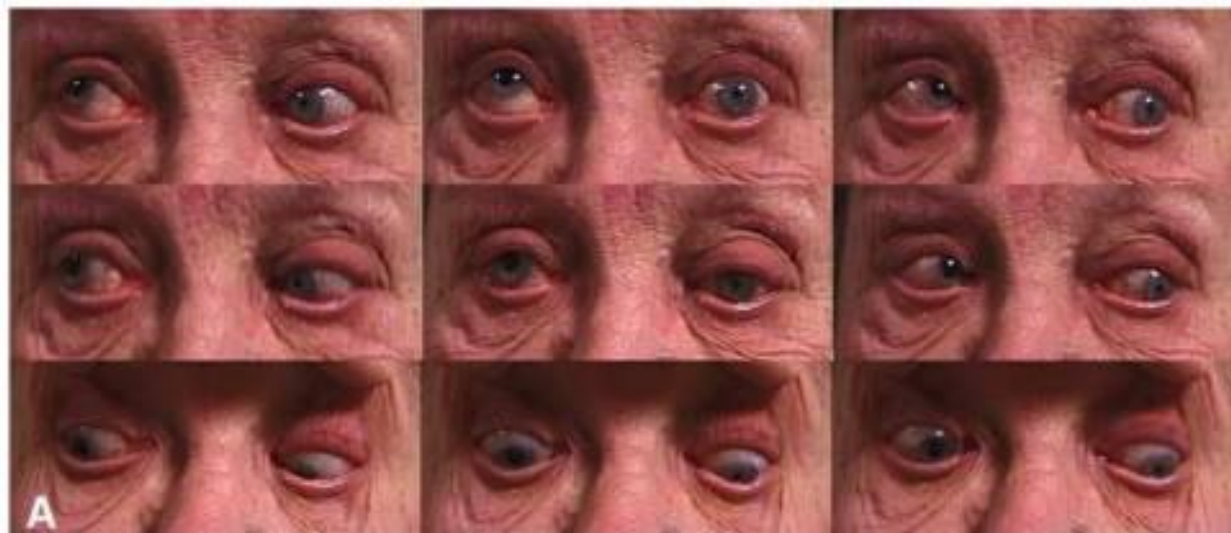Effect of aging on human rectus extraocular muscle paths demonstrated by magnetic resonance imaging.

Clark RA, Demer JL. [Am J Ophthalmol. 2002 Dec;134\(6\):872-8.](#)

Case 1: Elderly Strabismic

- A 85 year-old woman c/o vert diplopia post RE cat op – 2 ya (retrobulbar anesthesia).
- She had ptosis repair of the RUL
- s/p radiation for RT orbital lymphoma.
- HTN.
- On examination, VA was 20/20 in BE.

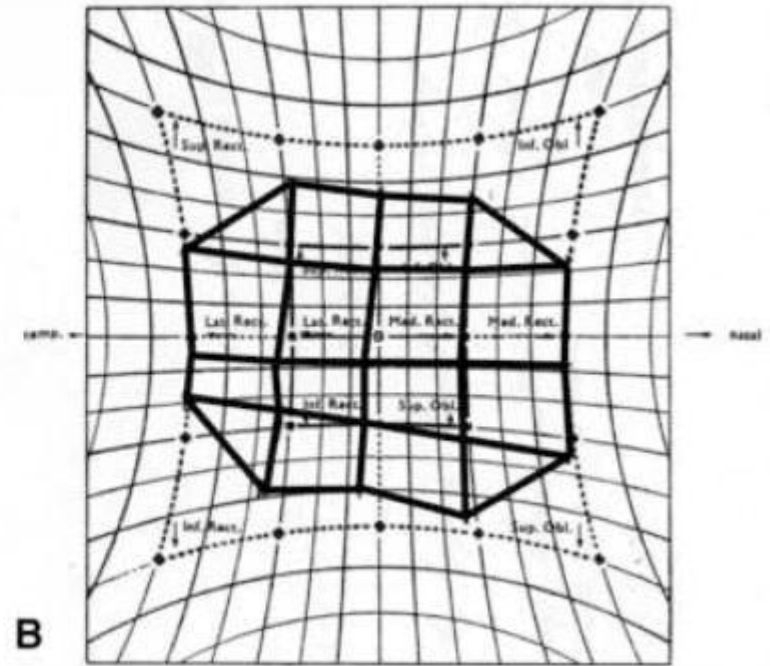
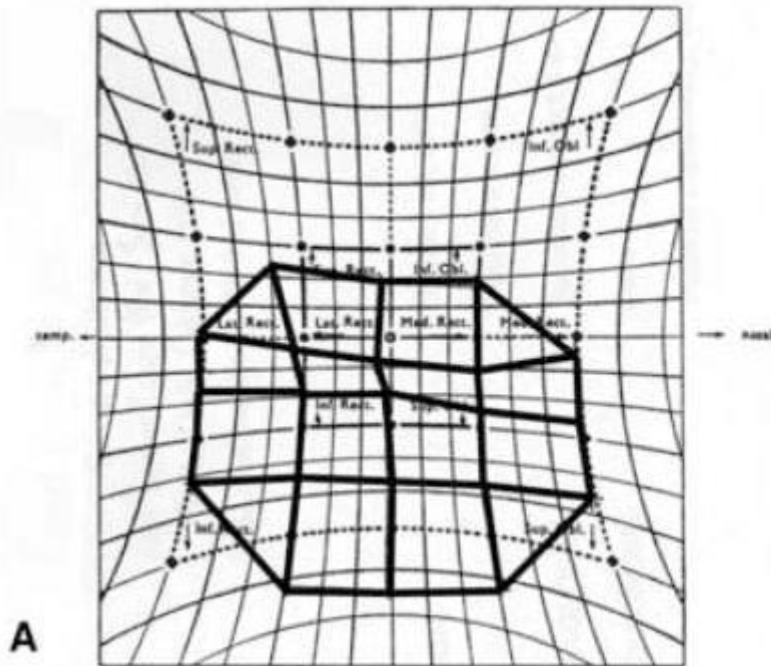
elderly strabismic pt before and after Sx repair
LT hypot on primary and LT gaze, and LT reduced elevation

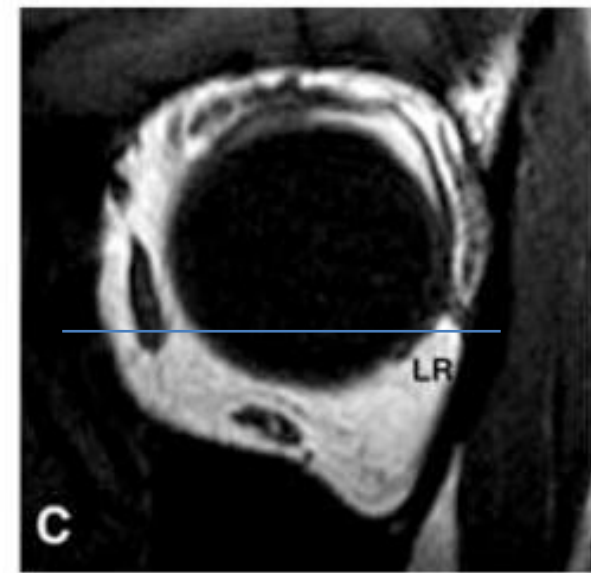
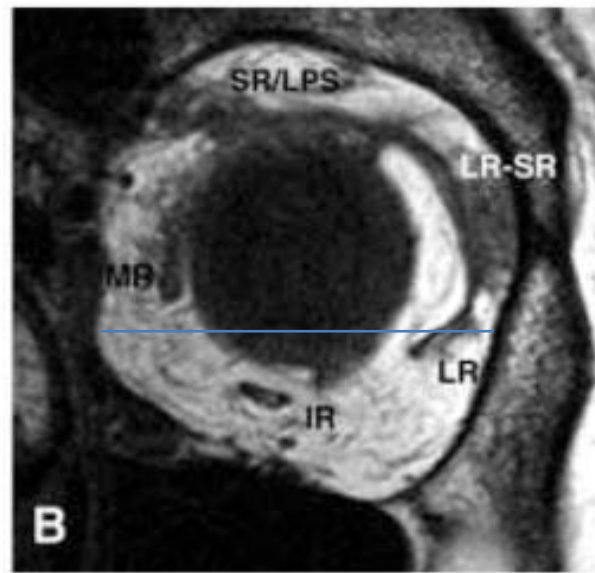
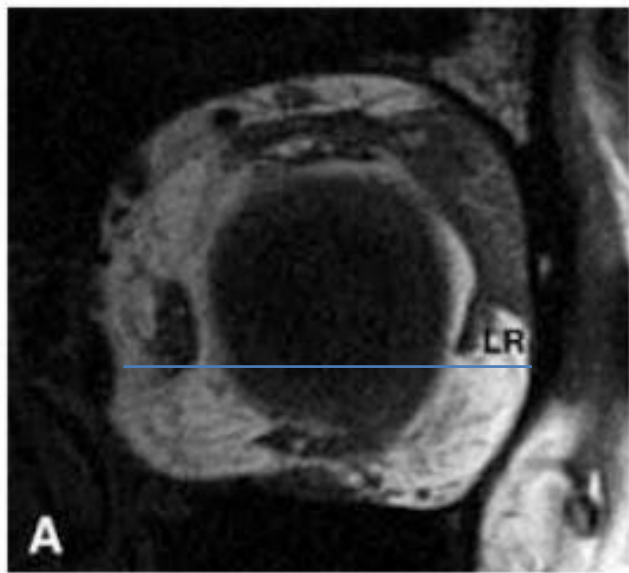


Hess screen of elderly strabismic subject 1,
showing left eye position with right eye fixating

Preoperative-LE

postoperative-LE





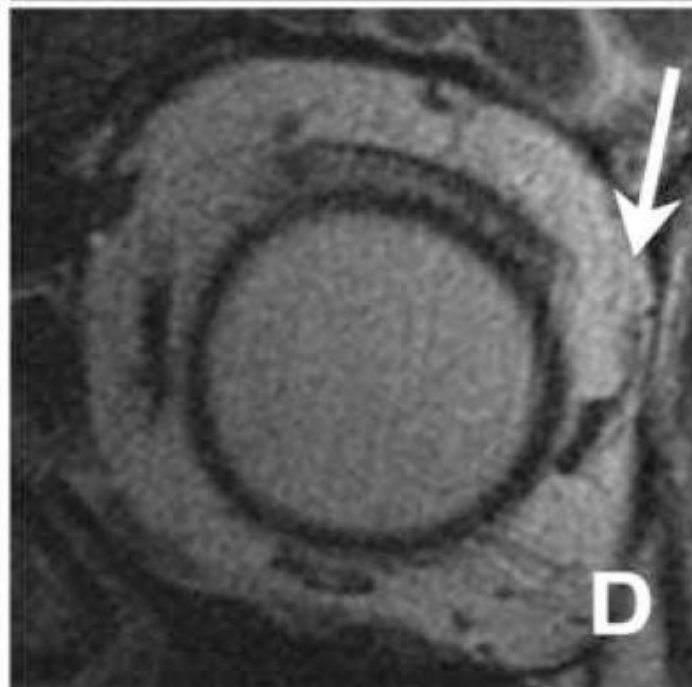
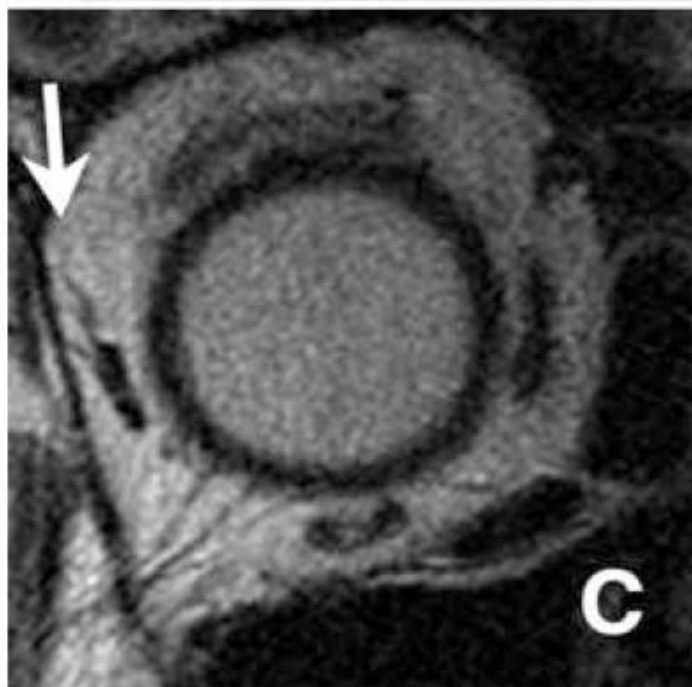
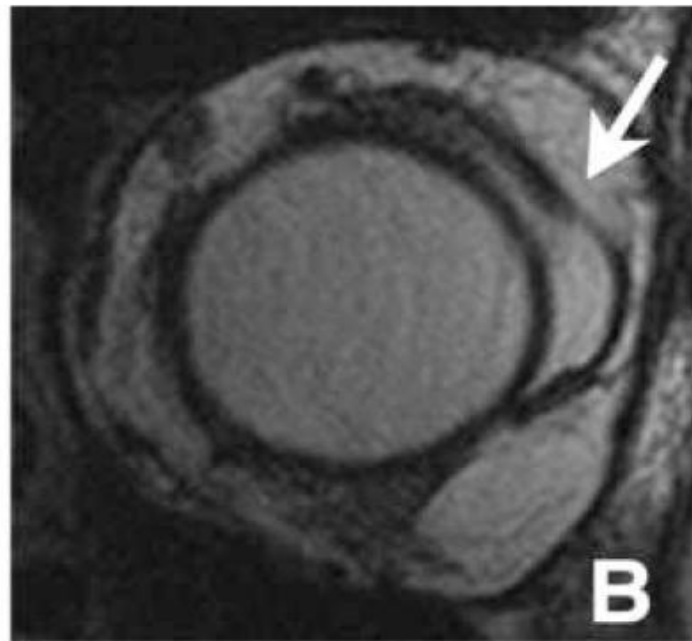
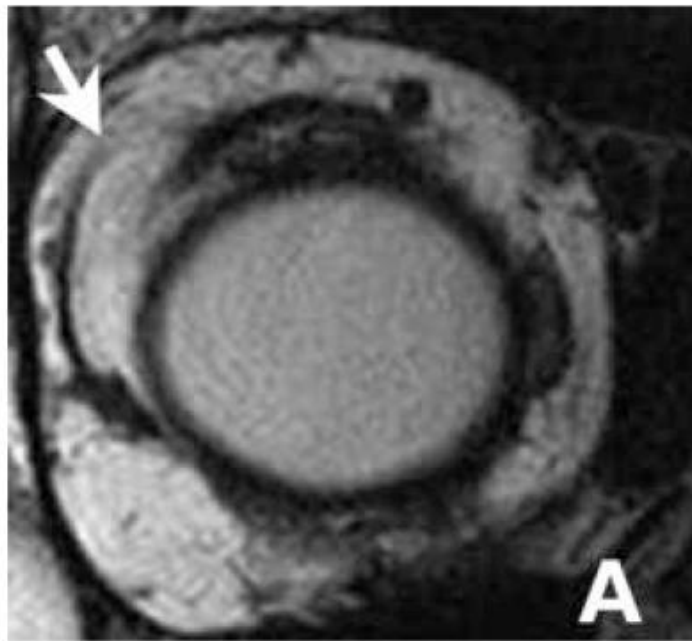
T1-MRI of left orbits showing LR-SR bands and positions of the four rectus muscles relative to the globe

A - Normal elderly control (74 , lrm 2.2 inf, vertical, LR-SR band thick, cont).

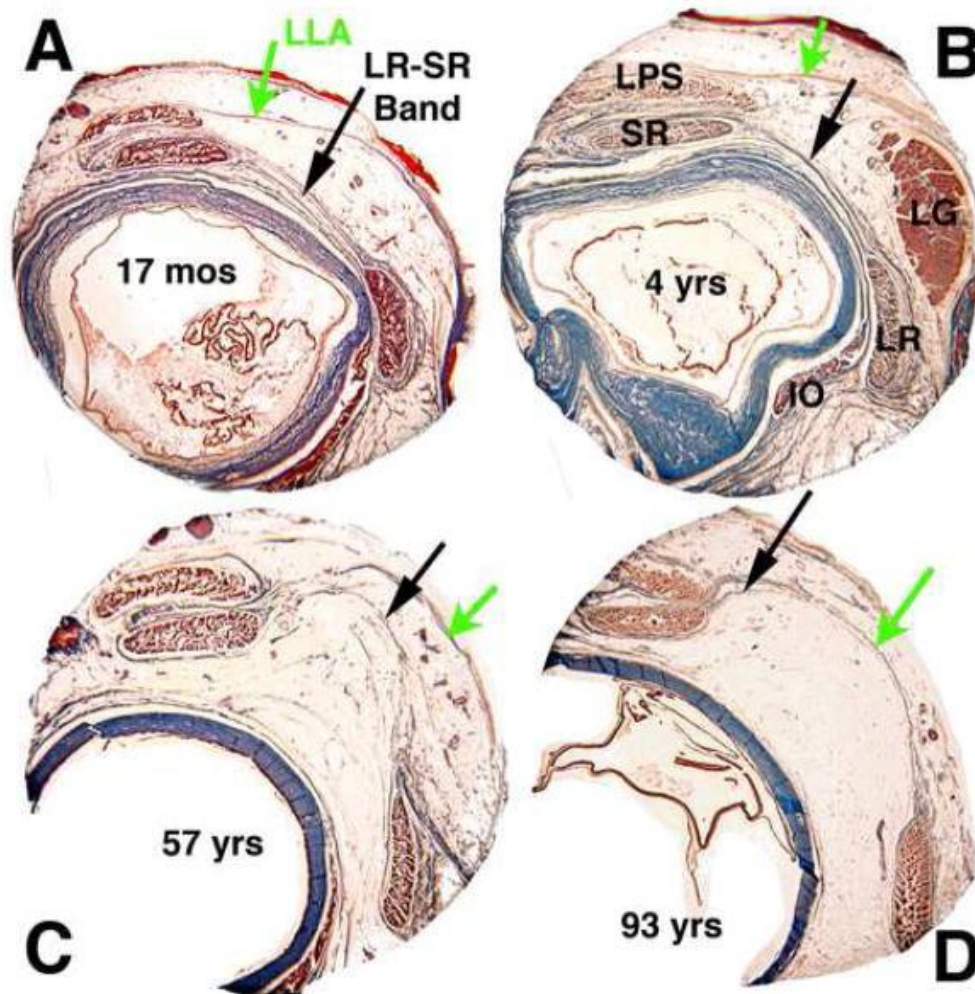
B - Elderly strabismic (85, LRM 7.6 inf, oblique, LR-SR band superotemporally displaced)

C - Strabismic myopic (63, LRM 7.4 mm inf, oblique, LR-SR band is thin and superotemporally displaced)

More
Examples of
LR-SR band
degeneration
in elderly
strabismic
subjects (T2-
MRI)



Histology: with ↑ age thinning, displaced superior-temporally displacement of LR-SR band. LRM displaced ↓ (LLA- levator aponeurosis)



surgery

- (1) superior transposition of the lateral rectus muscle insertion, and
- (2) suturing the margins of the LR-SR pulleys together (5-0 non-absorbable suture).